

Research Letter

Robotic Bladder Auto-transplantation in a Heart-beating Brain-dead Human Research Donor

Nima Nassiri, Giovanni Cacciamani, Inderbir S. Gill*

Human urinary bladder transplantation (BT) has not yet been successfully performed. Analogous organs, such as the uterus, have been transplanted, with a subsequent live birth reported [1]. The current gold standard for bladder replacement involves urinary diversion using a vascularized segment of bowel. Incorporation of bowel into the urinary tract inherently exposes patients to a variety of early and late metabolic, infectious, and renal functional consequences that can be severe, especially in immunosuppressed patients [2–5]. If technically feasible, BT might circumvent bowel-related complications in carefully selected patients already on, or anticipating, immunosuppression. In preparation for a United Network for Organ Sharing (UNOS)-approved phase 0 clinical trial of vascularized composite bladder allograft (VCBA) transplantation (NCT05462561), we developed a robotic bladder auto-transplantation technique.

Heart-beating brain-dead human research donors who were otherwise ineligible for clinical organ donation were identified and allocated by the local organ procurement organization (OneLegacy) after informed consent for research participation from the donor family. Institutional review board approvals were obtained through our institution (4B-21-5) and the OneLegacy Foundation. Robotic VCBA recovery and robotic auto-transplantation were performed by fellowship-trained, experienced transplant and robotic urologists under the guidelines of the IDEAL Collaboration. Robotic VCBA recovery involved radical prostatectomy and wide bladder mobilization with en bloc preservation of the vascular arcade, including the vesical vessels. Intracorporeal bladder hypothermia was performed using intravesical perfusion with cold saline (4°C) to minimize warm ischemia. Extracorporeal back-table reconstruction was used to create a single arterial inflow and single venous outflow via side-to-side anastomosis of bilateral internal iliac vessels. Robotic transplant vascular anastomoses were performed between the conjoined donor

internal iliac artery/vein and the recipient common iliac artery/vein, respectively. Various perioperative parameters were measured, including allograft perfusion on robotic visualization and indocyanine green immunofluorescence.

The operative time was 5.3 h, console time was 4.7 h, and estimated blood loss was 900 cm³. Back-table preparation and transplant vascular anastomosis times were 33 and 53 min, respectively. Final inspection revealed a pink healthy-looking bladder allograft with strong immunofluorescence (Fig. 1). The robotic approach was instrumental in optimizing visualization and fine dissection in the very deep pelvis.

The inaugural clinical BT candidate would be a highly selected patient with current or impending immunosuppression and a terminal, unusable bladder with benign pathology of neurogenic, infectious, or inflammatory etiology. To be clear, the need for lifelong immunosuppression currently limits the broader application of BT in typical radical cystectomy candidates with bladder cancer who are not immunocompromised and for whom de novo immunosuppression is contraindicated. Although we aim to perform BT in the adult setting initially, there could be important future implications for the pediatric urologic population. Since the transplanted bladder is denervated, it will principally serve as a urothelium-lined storage reservoir. Candidate patients must possess sufficient manual dexterity to perform clean intermittent catheterization or the Crede maneuver to void, as not uncommonly required after a standard neobladder construction.

This is the first report of vascularized BT in a heart-beating, brain-dead human donor, with excellent vascular viability after reperfusion, and is a necessary preclinical step before a first-in-human BT. If clinically successful, BT could offer a bowel-free, more normal bladder substitute in selected patients with bladder failure.

Conflicts of interest: The authors have nothing to disclose.

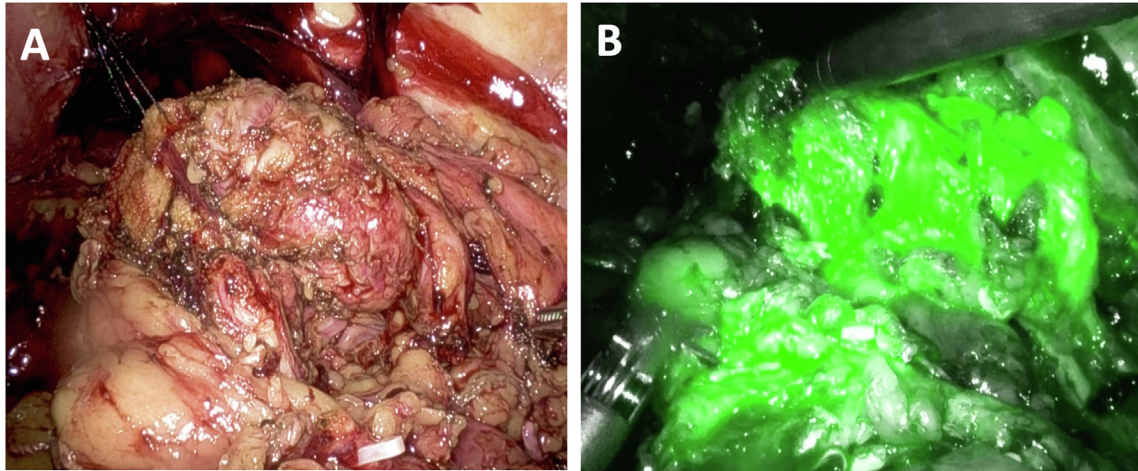


Fig. 1 – Documentation of post-transplant vasculaized composite bladder allograft integrity and vascular viability via (A) direct robotic visual inspection and (B) indocyanine green immunofluorescence.

Source of funding: This study was supported by a clinical research grant from the OneLegacy Foundation organ procurement organization (OL-RG-2022-05).

Peer Review Summary

Peer Review Summary to this article can be found online at <https://doi.org/10.1016/j.eururo.2023.06.004>.

References

- [1] Brännström M, Johannesson L, Bokström H, et al. Livebirth after uterus transplantation. *Lancet* 2015;385:607–16. [https://doi.org/10.1016/S0140-6736\(14\)61728-1](https://doi.org/10.1016/S0140-6736(14)61728-1).
- [2] Roth JD, Koch MO. Metabolic and nutritional consequences of urinary diversion using intestinal segments to reconstruct the urinary tract. *Urol Clin North Am* 2018;45:19–24. <https://doi.org/10.1016/j.ucl.2017.09.007>.
- [3] Clifford TG, Katebian B, Van Horn CM, et al. Urinary tract infections following radical cystectomy and urinary diversion: a review of 1133

patients. *World J Urol* 2018;36:775–81. <https://doi.org/10.1007/s00345-018-2181-2>.

- [4] Anderson CB, McKiernan JM. Surgical complications of urinary diversion. *Urol Clin North Am* 2018;45:79–90. <https://doi.org/10.1016/j.ucl.2017.09.008>.
- [5] Lawrentschuk N, Colombo R, Hakenberg OW, et al. Prevention and management of complications following radical cystectomy for bladder cancer. *Eur Urol* 2010;57:983–1001. <https://doi.org/10.1016/j.eururo.2010.02.024>.

Catherine & Joseph Aresty Department of Urology, USC Institute of Urology, Keck School of Medicine, University of Southern California, Los Angeles, CA, USA

*Corresponding author. Catherine & Joseph Aresty Department of Urology, Keck School of Medicine, University of Southern California, 1441 Eastlake Avenue, Los Angeles, CA 90089, USA. Tel. +1 323 8653794; Fax: +1 323 8650120. E-mail address: igill@med.usc.edu (I.S. Gill).

June 10, 2023