Check for updates

Baris Esen[1,3], Reza Lahiji[1], Dattatraya Patil[1], William Luke[1] and Viraj A. Master[1,2]

[1]Department of Urology, Emory University School of Medicine, [2]Winship Cancer Institute of Emory University, Atlanta, GA, USA, and [3]Department of Urology, Koc University School of Medicine, Istanbul, Turkiye

References

1 **Martínez-Salamanca JI, Huang WC, Millán I et al.** Prognostic impact of the 2009 UICC/AJCC TNM staging system for renal cell carcinoma with venous extension. *Eur Urol* 2011; 59: 120–7

2 **Bex A, Ghanem YA, Albiges L et al.** European Association of Urology guidelines on renal cell carcinoma: the 2025 update. *Eur Urol* 2025; 87: 683–96

3 **Lawindy SM, Kurian T, Kim T et al.** Important surgical considerations in the management of renal cell carcinoma (RCC) with inferior vena cava (IVC) tumour thrombus. *BJU Int* 2012; 110: 926–39

4 **Blute ML, Leibovich BC, Lohse CM, Cheville JC, Zincke H.** The Mayo Clinic experience with surgical management, complications and outcome for patients with renal cell carcinoma and venous tumour thrombus. *BJU Int* 2004; 94: 33–41

5 **Master VA, Ethun CG, Kooby DA, Staley CA 3rd, Maithel SK.** The value of a cross-discipline team-based approach for resection of renal cell carcinoma with IVC tumor thrombus: a report of a large, contemporary, single-institution experience: MASTER et al. *J Surg Oncol* 2018; 118: 1219–26

6 **McLeay MT 2nd, Roberson DS, Dorr M et al.** Growth kinetics of venous tumor thrombus from renal cell carcinoma. *J Urol* 2025; 214: 601–12

7 **Barashi NS, Friedman D, Pickersgill N et al.** Growth kinetics of venous tumor thrombus in patients with renal cell carcinoma. *Urol Oncol* 2024; 42: S6

Correspondence: Viraj A. Master, Department of Urology, Emory University, 1365 Clifton Road NE, Building B, Suite 1400, Atlanta, GA 30322, USA.
e-mail: vmaster@emory.edu

Supporting Information

Additional Supporting Information may be found in the online version of this article:

Figure S1. Flow diagram of patients included in the study.

Table S1. Demographics and clinical/imaging characteristics of patients in the study.

Table S2. Concordance between preoperative MRI (first column) and intraoperative ultrasound (top line) in assessing Mayo tumour thrombus level (n = 246).

Table S3. Multivariable logistic regression analysis to define independent predictors of tumour thrombus level discordance between preoperative MRI and intraoperative ultrasound.

Patient selection for prostate cancer focal therapy guided by mpMRI–PSMA PET concordance and pathology review

Focal therapy (FT) has gained increasing traction as a treatment strategy for carefully selected men with localized prostate cancer (PCa), offering the potential for meaningful oncologic control while minimizing functional morbidity – particularly urinary and erectile dysfunction – compared with whole-gland treatments [1,2]. However, optimal patient selection remains paramount. Multiparametric magnetic resonance imaging (mpMRI) is the foundation for tumour localization but may fail to detect bilateral clinically significant PCa (csPCa). Prostate-specific membrane antigen positron emission tomography (PSMA-PET) can refine tumour lateralization, potentially reducing the risk of undertreatment [3–5]. Likewise, pathology review plays a central role before proceeding with FT, as biopsy sampling performed in non-specialist settings may underestimate tumour grade or burden [6]. Nonetheless, to date, the combined value of PSMA-PET and centralized pathology review in the FT eligibility process remains unclear. Therefore, we examined whether discordance between mpMRI and PSMA-PET predicts bilateral csPCa at biopsy or final pathology after radical prostatectomy (RP) and the extent to which expert pathology review modifies FT eligibility.

We retrospectively analysed 307 men screened for FT (irreversible electroporation) between January 2024 and April 2026. Patients with a single mpMRI-visible lesion and biopsy-proven International Society for Urological Pathology (ISUP) grade group (GG) 2 PCa were considered for inclusion. Those with cribriform or intraductal carcinoma were excluded from the initial screening dataset. mpMRI positivity was defined as a Prostate Imaging Reporting and Data System (PI-RADS) score ≥ 3 (v2.1). PSMA-PET ([^{18}F]PSMA-1007) images were interpreted by two experienced nuclear

© 2026 BJU International.
Published by John Wiley & Sons Ltd. www.bjui.org
All rights reserved, including rights for text and data mining and training of artificial intelligence technologies or similar technologies.

medicine physicians in a non-blinded fashion. Scans were considered positive when focal tracer uptake exceeded the uptake of the spleen in the transitional zone or exceeded the uptake of the blood pool in the peripheral zone, according to PROMISE v2 criteria. After applying the selection criteria, 192 patients were included. All biopsies at our institution were performed by experienced urologists using standardized protocols. In rare selected cases (<2%), external biopsies considered incomplete (absence of systematic or targeted sampling) were repeated at our centre. Imaging concordance was defined as agreement between mpMRI and PSMA-PET on lesion location, whereas discordance included contralateral, bilateral, or absent PSMA-PET uptake. Biopsy concordance was defined as unilateral csPCa within the mpMRI-identified hemigland, whereas discordance included contralateral, bilateral, or absent csPCa. Differences in biopsy outcomes between patients with concordant and discordant imaging were evaluated using Fisher's exact test, and univariable logistic regression tested the association between imaging discordance and biopsy findings. In patients undergoing RP, bilateral tumour at final pathology was defined as bilateral clinically significant disease (ISUP GG ≥2) with organ-confined extension (pT2c) or contralateral extraprostatic extension (pT3a). Similarly, differences according to imaging concordance were assessed using Fisher's exact test, and univariable logistic regression tested the association with bilateral or contralateral disease at RP. A subgroup of 81 men with external biopsies underwent centralized review by an expert genitourinary uropathologist at our centre. Internal biopsies were evaluated by the same experienced pathologist and therefore did not routinely undergo additional review. FT eligibility required unilateral ISUP GG2 disease, with or without contralateral ISUP GG1. A sensitivity analysis stratified by PI-RADS score (3 vs 4–5) was performed. Discordant cases were further classified as "underestimation" (PSMA-PET showing contralateral/bilateral uptake) or "overestimation" (PSMA-PET negative on the mpMRI-indicated side). Group differences were assessed using Fisher's exact test.

Overall, PSMA-PET demonstrated right-sided uptake in 50 (26%) patients and left-sided uptake in 56 (30%), whereas 43 (22%) had bilateral uptake and 43 (22%) had negative scans. No lymph node uptakes were observed. Median time from biopsy to PSMA-PET was 1.6 months (interquartile range 1–2.2). Among patients with concordant mpMRI–PSMA-PET imaging (n = 120), biopsy-confirmed csPCa location matched the imaging-indicated lesion in 103 (86%) cases; among patients with discordant imaging (n = 72), this occurred in 53 (74%) cases. Discordant imaging was associated with higher rates of discordant biopsy findings (26% vs 14%) and independently predicted discordant biopsy location (odds ratio 2.23; 95% confidence interval 1.07–4.64, P = 0.029). Among patients undergoing RP (n = 33), 26 (79%) had pT2c or pT3a contralateral disease, and this occurred more frequently in men with mpMRI–PSMA-PET discordance (19/21 [90%]) than in those with concordant imaging (7/12 [58%]). Discordance strongly predicted bilateral or contralateral tumour involvement at RP (odds ratio 6.79; 95% confidence interval 1.06–43.4; P = 0.030). Of 81 patients initially deemed eligible for FT based on external biopsies, centralized pathology review reclassified 17 (21%) as ineligible because they had ISUP GG1 (n = 4 [24%]), bilateral ISUP GG2 (n = 6 [35%]), or ISUP GG3 (n = 7 [41%]) disease. Overall, 112 patients were considered eligible once the screening process was completed, and 60 (54%) underwent FT. Among the remaining 52 patients, reasons for not performing FT included unfavourable tumour characteristics, such as apical location, large region of interest, or suspicion of extracapsular extension on mpMRI (n = 30 [58%]), physician or patient preference (n = 16 [31%]) and prior disobstructive prostate surgery (n = 6 [11%]) (Fig. 1). Cancer detection rate on biopsy did not differ significantly according to PI-RADS score (91% [32/35] for PI-RADS 3 vs 96% [150/157] for PI-RADS 4–5; P = 0.4). Imaging concordance was numerically higher among PI-RADS 4–5 lesions (65% [102/157]) than PI-RADS 3 lesions (51% [18/35]), although this was not statistically significant (P = 0.17). Among the 72 discordant cases, underestimation (PSMA-PET showing bilateral/contralateral uptake) was more common than overestimation (PSMA-PET negative on the mpMRI-indicated side): 71% versus 29% overall, with a similar distribution across PI-RADS groups (65% vs 73%; P = 0.5).

Accurate identification of truly unilateral csPCa remains a prerequisite and a major unmet need for the safe implementation of FT. Although mpMRI-guided biopsy has improved patient selection, residual uncertainty regarding contralateral disease persists and may compromise oncological safety. Our findings provide two relevant insights. First, mpMRI–PSMA-PET concordance is a robust indicator of unilateral disease, whereas discordance identifies patients at increased risk of contralateral or bilateral csPCa. These results complement previous evidence regarding the role of PSMA-PET in improving risk stratification and further support its integration into pre-treatment assessment of FT candidates [4,5]. Indeed, Geboers et al. demonstrated that adding PSMA-PET to mpMRI and biopsy improved diagnostic accuracy and correctly excluded more than half of non-ideal candidates for hemi-ablation [7], and Maurer et al. reported that 12% of patients were excluded from FT because of disease upstaging on PSMA-PET [3]. Second, centralized pathology review substantially refines FT eligibility, with nearly one-fifth of patients reclassified after expert reassessment, most commonly due to upgrading or bilateral disease. This confirms that biopsy interpretation remains a critical vulnerability and that expert uropathology review provides clinically relevant refinement. Our findings align with prior evidence

 © 2026 BJU International.

1464410x, 2026, 5, Downloaded from https://bjui-journals.onlinelibrary.wiley.com/doi/10.1111/bju.70420 by University Of Cape Town, Wiley Online Library on [06/11/2026]. See the Terms and Conditions (https://onlinelibrary.wiley.com/terms-and-conditions) on Wiley Online Library for rules of use; OA articles are governed by the applicable Creative Commons License

Fig. 1 Sankey diagram illustrating the screening process of 192 potential candidates for focal therapy (FT). 120 patients had concordant multiparametric magnetic resonance imaging (mpMRI)–prostate-specific membrane antigen positron emission tomography (PSMA-PET), whereas 72 had discordant imaging findings. Centralized pathology review was performed in 81 men. At the end of the screening process, 112 men were considered eligible for FT and 80 were deemed not suitable. Among the eligible patients, 60 ultimately underwent FT, and 52 did not receive FT for other reasons. Note: Percentages on the screening–eligibility flows are proportions of the total screened cohort (n = 192); percentages in the FT panel are proportions of eligible patients (n = 112); percentages for reasons for not receiving FT are proportions of patients who did not receive FT (n = 52). Reasons for not receiving FT are tumour location or extent (30/52 [58%]), physician or patient preference (16/52 [31%]), and prior disobstructive surgery (6/52 [11%]).

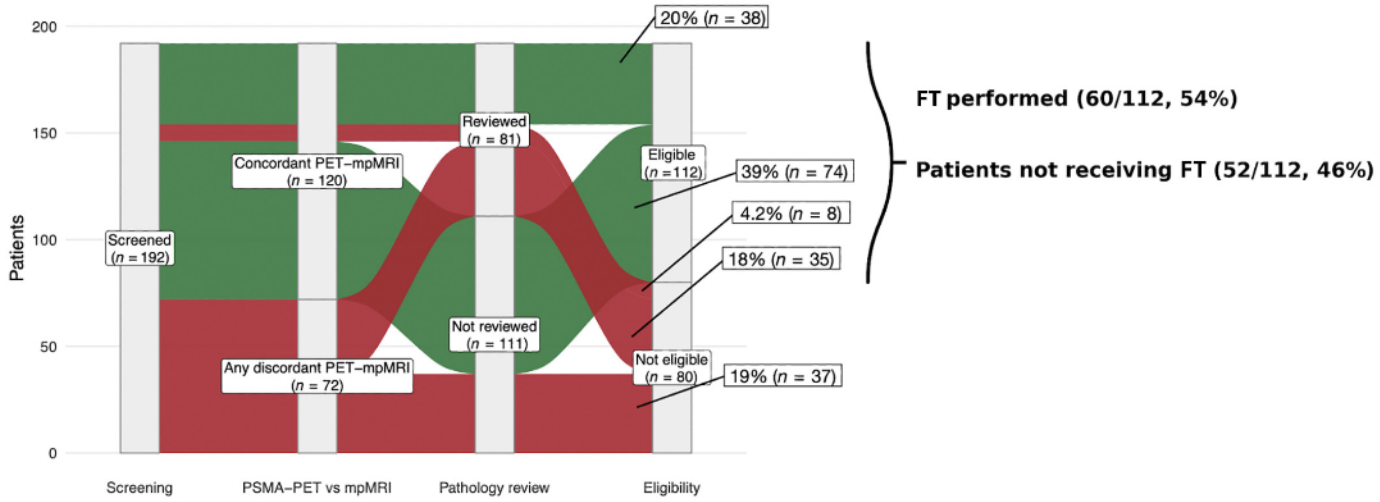

demonstrating the clinical impact of second-opinion pathology in localized PCa management [6,8]. Within the FT setting, only Benidir et al. have shown that expert reassessment modifies high-intensity focused ultrasound eligibility in nearly 20% of cases [9]. Importantly, approximately half of the patients did not receive FT despite meeting eligibility criteria. Patients often opted for radical treatment after extensive counselling with physicians, identifying RP or radiotherapy as a more appropriate therapeutic approach. Anatomical tumour features represented another major reason for not performing FT because of the risk of not achieving adequate oncological control. Lastly, in patients with a history of disobstructive prostate surgery, FT was avoided because of surgery-related tissue changes that could result in technical challenges.

This study has limitations. First, the relatively small sample size and limited number of events precluded multivariable analyses. Second, patients with ISUP GG3 disease were not included, reflecting our institutional practice of restricting FT to carefully selected patients with unilateral ISUP GG2 disease. Third, given the study design and relatively short follow-up, oncological and functional outcomes were not assessed; longer follow-up will be necessary to determine whether this selection strategy translates into appropriate clinical outcomes. Fourth, as PSMA-PET was performed after biopsy, some tracer uptake may have been influenced by post-biopsy inflammatory changes. Fifth, our RP-based validation was limited to men already selected for FT; future studies in an unselected RP cohort should confirm the generalizability of mpMRI–PSMA-PET discordance as a predictor of bilateral disease. Finally, as this was a retrospective single-centre study conducted at a high-volume tertiary referral centre, our findings may have limited generalizability and remain subject to potential work-up and verification biases.

In conclusion, concordance between mpMRI and PSMA-PET appears to predict the presence of unilateral csPCa, whereas centralized pathology review modifies management in approximately one-fifth of patients. Integrating these strategies may improve the accuracy of FT candidate selection, although validation in larger cohorts with extended follow-up is needed to confirm the impact of this approach on long-term oncological outcomes.

Disclosure of Interests

None declared.

Data Availability Statement

The data that support the findings of this study are available on request from the corresponding author. The data are not publicly available due to privacy or ethical restrictions.

1464410x, 2026, 5, Downloaded from https://bjui-journals.onlinelibrary.wiley.com/doi/10.1111/bju.70420 by University Of Cape Town, Wiley Online Library on [06/11/2026]. See the Terms and Conditions (https://onlinelibrary.wiley.com/terms-and-conditions) on Wiley Online Library for rules of use; OA articles are governed by the applicable Creative Commons License

Armando Stabile[1,2], Michele Brancaccio[1,2], Pietro Scilipoti[1,2], Francesco Maria Barletta[1,2], Simone Scuderi[1,2], Leonardo Quarta[1,2], Andrea Cosenza[1,2], Paolo Zaurito[1,2], Maria Elena Porzi[1,2], Giulio Imperiale[2,3], Giorgio Brembilla[2,3], Francesco De Cobelli[2,3], Cristiano Pini[2,4], Arturo Chiti[2,4], Maurizio Colecchia[2,5], Francesco Montorsi[1,2], Giorgio Gandaglia[1,2] and Alberto Briganti[1,2]

[1]Department of Experimental Oncology/Unit of Urology; URI, IRCCS Ospedale San Raffaele, [2]Vita-Salute San Raffaele University, [3]Department of Radiology, [4]Department of Nuclear Medicine, and [5]Department of Pathology, IRCCS Ospedale San Raffaele, Milan, Italy

A.S. and M.B. contributed equally to this work.

References

1 **George AK, Miocinovic R, Patel AR et al.** Irreversible electroporation for prostate tissue ablation in patients with intermediate-risk prostate cancer: results from the PRESERVE trial. *Eur Urol* 2025; 89: 57–68

2 **Scheltema MJ, Geboers B, Blazevski A et al.** Median 5-year outcomes of primary focal irreversible electroporation for localised prostate cancer. *BJU Int* 2023; 131: 6–13

3 **Maurer A, Muehlematter UJ, Sivakumar T et al.** High-intensity focused ultrasound in prostate cancer: can PSMA PET improve focal therapy outcomes? *J Nucl Med* 2025; 67: 239–45

4 **Nicoletti R, Alberti A, Gauhar V et al.** Is there a role of PSMA-PET in focal therapy planning and follow-up? *Prostate Cancer Prostatic Dis* 2025; 29: 28–35

5 **Liu J, Harewood L, Bagguley D et al.** Early results from the CONFIRM trial: utility of prostate-specific membrane antigen positron emission tomography/computed tomography in active surveillance for prostate cancer. *Eur Urol Oncol* 2025; 8: 1118–25

6 **Bravi CA, Vertosick E, Tin A et al.** Relative contribution of sampling and grading to the quality of prostate biopsy: results from a single high-volume institution. *Eur Urol Oncol* 2020; 3: 474–80

7 **Geboers B, Meijer D, Counter W et al.** Prostate-specific membrane antigen positron emission tomography in addition to multiparametric magnetic resonance imaging and biopsies to select prostate cancer patients for focal therapy. *BJU Int* 2024; 133: 14–22

8 **UsónJunior PLS, Macarenco RS e S, Oliveira FN, Smaletz O.** Impact of pathology review for decision therapy in localized prostate cancer. *Clin Med Insights Pathol* 2017; 10: 1179555717740130

9 **Benidir T, Wood A, Lone Z et al.** The feasibility and value of a focal therapy multidisciplinary tumor board, including radiographic and pathological overreads in refining the selection for high intensity focused ultrasound in prostate cancer patients. *Urology Practice* 2024; 10: 372–7

Correspondence: Armando Stabile, Department of Urology and Division of Experimental Oncology, URI, Urological Research Institute, IRCCS San Raffaele Scientific Institute, Via Olgettina, 60, 20132 Milan, Italy.
e-mail: armando.stabile88@gmail.com

 © 2026 BJU International.

1464410x, 2026, 5, Downloaded from https://bjui-journals.onlinelibrary.wiley.com/doi/10.1111/bju.70420 by University Of Cape Town, Wiley Online Library on [06/11/2026]. See the Terms and Conditions (https://onlinelibrary.wiley.com/terms-and-conditions) on Wiley Online Library for rules of use; OA articles are governed by the applicable Creative Commons License