

Review

Percutaneous nephrolithotomy – the puncture

Peter Alken 

Department of Urology, Klinik für Urologie und Urochirurgie, Universitätsmedizin Mannheim, Mannheim, Germany

Abstract Objective

To determine what importance is given to the puncture and assistive technologies in percutaneous nephrolithotomy (PNL) in the current urological literature.

Methods

PubMed was searched for English publications and reviews for the keywords: ‘percutaneous nephrolithotomy’, ‘percutaneous nephrostomy’, ‘puncture’. The search was limited to the last 5 years, January 2016 until February 2021. Based on 183 abstracts, 121 publications were selected, read, and reviewed. References, older or seminal papers were read and cited if they contributed to a better understanding. A total of 198 references form the basis of this narrative review.

Results

The puncture is frequently referred to as the most crucial part of PNL. In contrast, the influence of the puncture on the failure rate of PNL and the specific puncture-related complications seems to be low in the single-digit percentage range. However, there are no universally accepted definitions and standards measuring the quality of puncture. Consequently, the impact of the puncture on general PNL complications, on stone scores predicting success rates and on learning curves evaluating surgeons’ performance have not been systematically studied. Assistive technologies rely on fluoroscopy and ultrasonography, the latter of which is becoming the preferred imaging modality for monitoring the entire procedure. Needle bending, a problem relevant to all puncture techniques, is not addressed in the urological literature.

Conclusions

The importance attached to puncture in PNL in the current urological literature is subjectively high but objectively low. Some basics of puncture are not well understood in urology. Disciplines other than urology are more actively involved in the development of puncture techniques.

Keywords

Endourology, fluoroscopy, kidney stones, needle bending, nephrostomy, percutaneous nephrolithotomy, puncture, renal access, ultrasonography, urolithiasis, #KidneyStones, #UroStone, #EndoUrology

Introduction and Search Strategy

The most critical aspect of percutaneous nephrolithotomy (PNL) is the establishment of access. This is a standard opening remark of many publications [1–3]. Several reviews on the puncture and intraoperative assistive technologies have been published in recent years [2–5]. They concentrate on technical details but rarely on data dealing with procedural details, problems, and pitfalls of the puncture. The present narrative review focusses on the importance, consequences and techniques of the puncture and assistive technologies reflected in the most recent literature.

PubMed was searched for English publications and reviews for the keywords: ‘percutaneous nephrolithotomy’,

‘percutaneous nephrostomy’, ‘puncture’. The search was limited to the last 5 years, January 2016 until February 2021.

Based on 183 abstracts, 121 publications were selected, read, and reviewed. Relevant references of the included studies and reviews were read. Older or seminal papers were read and cited if they contributed to a better understanding. Adapted to editorial rules, 50 selected publications were referenced. The full set of 198 references that form the basis of the present review can be obtained from the author.

Due to a plethora of different terms, a uniform nomenclature is used.

- Puncture: fluoroscopic-guided puncture (FP), ultrasonography (US)-guided puncture (UP), combined fluoroscopic and US-guided puncture (FUP),
- Access (puncture and dilatation): fluoroscopic access (FA), US access (UA), fluoroscopic and US access (FUA),
- Complete PNL (from beginning to end): fluoroscopic PNL (FPNL), US PNL (UPNL), fluoroscopic and US PNL (FUPNL).

THE 'WHO'S AND HOW'S' of PUNCTURE

Imaging is the key to puncture. Availability, medical education, and professional standards govern the imaging technique used. Initially fluoroscopy was the only available technique. Radiologist established the access because they had the equipment. Fluoroscopy is still favoured, especially in countries where US, introduced in the late 1970s, was not mastered, such as in the USA. There, in 2016, it was still considered as 'having serious limitations hindering a general application'. UA, often in combination with fluoroscopy (FUA), was initially used only where urologists had access to both imaging modalities for daily urological routine [6].

The BAUS PNL registry put an end to debates on the 'who's and how's' of puncture: the outcome of 5211 PNLs was essentially identical, regardless of access establishment by radiologists or urologists and under fluoroscopic or US control [7]. The quality of access is not a question of professions and imaging techniques but of proficiency and practice. So if the 'who's and how's' do not matter, why is it a 'crucial task of obtaining PNL access' [7]?

IMPACT OF THE PUNCTURE

There is a vague distinction in the literature between the action of a correct puncture and the strategy of a proper access. All steps of PNL have their own problems and some of them, such as transfusion requirements, are difficult to attribute to a single step and cause. Due to under reporting or aggregation of the complications of the whole procedure, reliable data on the problems of the individual steps are generally not available. The difficulties of the puncture should be reflected in the negative effects of PNL, i.e. complications, in the expectations, i.e. stone scores predicting success, and in the surgeons' performance, i.e. learning curves. Direct negative impacts of the puncture are: i) access failure, ii) vascular lesions leading to embolisation, and iii) lesions of adjacent organs.

Access Failure

Standard papers, large series or reviews infrequently report on access failure or abandoned cases. In the BAUS registry, 50/5211 (1%) failures accounted for 21% of the 243 abandoned cases [7].

FP failed in 4.5% (35/782) in a large series [8]. In all, 2.8% (10/357) of failures with UPNL in obese patients required a switch to FP [9]. A randomised controlled trial (RCT) on FPNL ($n = 145$), UPNL ($n = 147$) and FUPNL ($n = 146$) reported comparable access failure rates of 2.1%, 3.4% and 2.1%, respectively [1]. Rather rigid success criteria were applied in a small quasi-experimental study conducted by an experienced group. The overall failure rate of UP in 47 patients treated by a fellow was 9%. It increased to 28% when a imperfect transpapillary access was considered a failure [10].

With different techniques, experience, study design, and a presumably high number of unreported cases, the access failure rate varies between 0% and 9% and more. Reporting is not standardised.

Vascular Lesions

An arterial vascular lesion during the puncture is a rare, probably frequently unrecognised event. Many PNL papers present the typical statistical correlations of blood loss vs stone volume and type, number of tracts, or duration of procedure. The real causes necessitating active intervention by embolisation are not known. The frequency of embolisation varied between 0% and 3% in representative series. It was 0.25% (13/5211) in the BAUS PNL registry [7]. In a RCT with 18-F tracts the embolisation frequency was 1.4% (two of 145) with FPNL, 0.7% (one of 147) with UPNL, and 0.7% (one of 146) with FUPNL [1]. No embolisation was necessary in a RCT using 30-F tracts in two groups with UPNL prone (132) or supine (129) position, but in 1.5% (two of 131) with FPNL in the prone position [11].

No embolisation was reported in a recent series of 504 PNLs in children with tract sizes between 30 and 14 F [12].

Anomalous arterial configurations have never been described, neither by proponents of Doppler US control during UP nor in the angiographies during embolisation. Thus, arterial lesions are always just bad luck and rarely occur. The number of embolisations is small, the frequency variable, and not dependent on access site or tract size.

One publication dealing with embolisation is worth mentioning. In a series of 1554 PNLs, a selected group of 53 patients who required transfusions were evaluated by postoperative CT. Of these, 21 (1.4%) had embolisation and 32 did not. On multivariate analysis, the only significant difference between the two groups was a tract inside or outside Brödel's avascular plane: only seven of 21 (33.3%) in the embolised group but 21 of 32 (65.6%) in the non-embolised group had what the authors called a 'correct in-plane puncture'. They concluded that an infundibular puncture carries a higher risk of arterial lesions [13].

Vascular lesions are at the centre of the debate on papillary vs non-papillary access. The group from Patras [14] did not re-invent renal anatomy. They merely realised that the risk of hitting a larger vessel is low with a non-papillary access. It cannot be negligible, as bleeding requiring embolisation has been reported even with a supposedly precise transpapillary approach. They stated that the standard transpapillary approach is based on the studies of Sampaio *et al.* first published in 1990. However, by that time several thousand PNLs had been performed worldwide [6]. The standard access was based on the old open surgery nephrostomy experience, passing a forceps from inside the collecting system through the calyx (where else?) to the kidney surface and pulling the nephrostomy tube in.

Lesions of Adjacent Organs

Lesions of adjacent organs occur due to lack of control of the puncture path.

Rare colon lesions have become a publication field for case reports. With CT as standard preoperative imaging, a retrorenal colon should be routinely detected and lesions avoided. Pleural lesions seem to have become an undesirable but accepted part of a supracostal access. The incidence can be as high as 26.6% or as low as 0% if the puncture is performed on the lateral half of the ribs [15].

A recent meta-analysis showed hydrothorax in 5.77% (52/901) for supracostal vs 0.53% (6/1127) for subcostal accesses [16].

With US all neighbouring organs within the planned puncture path can be detected [17]. Surprisingly, the 'all-seeing needle' has not yet been used to see the pleura during a supracostal access.

In summary, the puncture is rarely mentioned as a systemic clinical problem of PNL. Failed access is relatively frequent among the rare major puncture related problems.

STONE SCORES AND LEARNING CURVES

None of the stone scoring systems includes aspects of the puncture, as if the puncture does not contribute to success or complications of PNL.

Classical publications on FPNL learning curves show that operating room (OR) time-related competence is reached after 60 cases, with acceptable radiation doses after ~120 cases. Some recent clinical papers dealt with learning curves for UP [18], FPNL [19], UPNL [20] and FUPNL [21].

The UPNL learning curve of a single PNL-qualified surgeon showed a significant decrease in access time and number of puncture attempts between the 61st to 120th and the 121st to 180th procedure. These changes were within reasonable limits

(4.4 to 1.3 min and 2.1 to 1.2 attempts). The increase in the stone-free rate from 68.3% to 93.3% showed a typical learning curve problem [20]. The authors assume that competence and excellence in UPNL is achieved after 60 and 120 operations, respectively.

Novices usually achieve good success and low complication rates in their initial cases, with proper assistance! This reflects appropriate mentorship programmes and, most of all, a responsible clinical support [19].

The measurement of parameters that properly document the performance of the puncture is not standardised (Fig. 1). There is no systematic evaluation for any of the puncture techniques [22]. The few available data are very mixed. For example, the reported average puncture time ranges from a few seconds to half an hour [23] due to lack of standardisation. Percutaneous access training models principally allow the measurement of puncture performance. However, a recent review on PNL simulator models concluded that the educational impact on clinical performance has not been accurately evaluated [24].

The slope of the clinical learning curves is likely to be in the puncture. Measuring and manipulating the typical surrogate markers, such as OR time, fluoroscopy times and radiation, will have limited impact on learning curves. The puncture is an educational problem. This is also evident in the discussion of a recent paper on virtual reality training [25].

Imaging Techniques

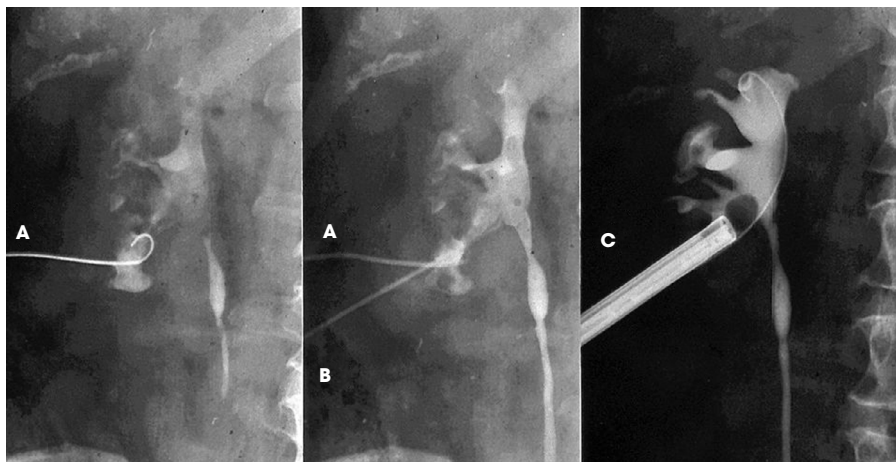
Fluoroscopy

The FP was the globally most frequently applied technique in the Clinical Research Office of the Endourological Society (CROES) data on >5000 cases. Collected >10 years ago, they are outdated. FP can be performed monoplanar and in three different bi-planar variants: 'bull's eye', triangulation, and a hybrid technique with different advantages [23]. Improvement of FP techniques has four goals: reducing radiation, moving the surgeon's hands out of the radiation field, improving targeting accuracy, and stabilisation of the needle tract.

Details focus on the different positions of the C-arm and the way to approach the right calyx.

Most of the suggestions are merely modifications of two old concepts: trigonometric principles for estimating puncture depth were described in 1998 [26] and are applied in various FP techniques. In 2003, Bilen *et al.* [27] coupled a laser beam to the C-arm to replace temporarily fluoroscopy for optical needle alignment during advancement. This recently culminated in the Automated Needle Targeting (ANT-X) system. The term 'robot' is used; however, it is an end-effector, a complex needle holder mounted on the operating table. Fed with the data from fluoroscopy, it aligns the needle

Figure 1 Low quality percutaneous puncture (A) possibly causing torque, bleeding, etc. corrected by good quality anatomically oriented puncture (B) during the same procedure. Nephrostomogram after complete removal of the staghorn stone (C). A standard publication on PNL would not mention puncture A or B as influencing the success or complication of the case and series



to the correct direction and depth in the bull's eye technique. The needle is advanced manually [28].

Sometimes simple modifications achieve comparable improvements to high-tech solutions. In a RCT a retrograde air pyelogram instead of a contrast pyelogram improved fluoroscopy time, radiation dose, access time and number of puncture attempts compared to the conventional technique [29]. Performed antegrade, it could even save the time of retrograde manipulation [30]. The 'kissing' or double-needle technique revives the principle of an old technique in which the collecting system of a silent, obstructed kidney, not accessible retrogradely is opacified by a preceding vertical fine needle puncture.

Although FP has been in use for > 50 years, suggestions for improvement keep appearing. The technique seems to serve its purpose, is not perfect, and not suitable for fundamental changes but only for modifications.

Ultrasonography

In the past, all patients were examined by plain film and IVU showing the stone and collecting system. Now, that non-contrast CT is considered the necessary plain image and 'as low as reasonably achievable' (ALARA) is to be respected, US is the only technique that routinely shows the collecting system.

C-arm fluoroscopy, used in a way to limit radiation, offers two-dimensional (2-D) images of a 3-D space. The images are generated step-by-step, taken in different planes. The surgeon must mentally assemble them into a 3-D space, and has to control and correct the needle position in this virtual space.

In contrast, US provides continuous 2-D views into the 3-D space. The images are generated in real time, can be

repeated, and immediately taken in different perspectives. The limitations currently come with increasing skin-to-target distance and non-dilatated collecting systems.

Several reviews have shown that US competes well with fluoroscopy. A recent comparison of UA vs FA showed the expected reduction of radiation, but otherwise no difference in success and complication rates [5]. Another review from 2018 concluded that both fluoroscopy and US guidance are valid options, more so when combined [1]. A 2017 review even went further, concluding that US offered shorter puncture time, higher first puncture success rates, and fewer complications compared to fluoroscopy [31].

In the last 5 years, 16 publications reported on 1860 cases of UPNL in adults and children. A RCT comparison of FPNL ($n = 145$), UPNL ($n = 147$) and FUPNL ($n = 146$) showed only a longer access time for FUPNL, while all other very detailed parameters were not different [1]. A RCT of prone UPNL ($n = 132$), supine UPNL ($n = 129$) and prone FPNL ($n = 131$) had clinically irrelevant outcome differences and concluded, 'the current standard practice of using US is a reliable tool of guidance during PCNL' [11].

A few selected studies show possibilities and limits.

By switching from FP to UP the PNL-experienced surgeon can reduce his/her fluoroscopy-time by 75% within the first 15 cases [18]. UPNL works well in children who benefit most from radiation reduction [32]. An exceptional series of 72 UPNL in patients with spinal deformities demonstrates a major advantage of US. Even in these anatomical difficult cases, the most appropriate access point can be determined in real time by US regardless of patients' position [33].

Obesity is the most frequent problem for US. A learning curve publication shows that an experienced PNL surgeon needs ~50 cases to reach a success rate of 80% in the body mass index (BMI) <40 kg/m² group, but an experience of ~140 cases to achieve the same success rate in patients with a BMI of >40 kg/m² [21]. Fluoroscopy should be available if needed, as shown by a comparison of FA and UA [34]. In polycystic kidney disease, a failure rate of 30% of UPNL has been described and FPNL was superior [35]. These should be good cases to target the tip of a flexible scope in a calyx, as recently described [36].

Few studies used Doppler US to avoid vessels or contrast-enhanced US or 3-D US to improve the puncture. However, the importance of these techniques is minimal, considering that they have been available for many years.

Ideally, with US all areas of interest, kidney, stone, adjacent organs, and devices are visible in real time. These are essential parameters to qualify US as the tool for further development.

Special Techniques

Retrograde and Endoscopic Techniques

There are two retrograde techniques to establish or assist percutaneous access to the kidney.

Some urologists welcomed the retrograde puncture technique introduced in the early 1980s, as it freed them from the puncturing radiologist. The few followers even made supracostal accesses. In the late 1980s, the technique was modified by adding ureteroscopy (URS) to select the access calyx. This was recently described as URS-assisted retrograde nephrostomy (UARN). The latest modification was cutting the tract with a Laser from inside [37]. These procedures require several additional tools and actions compared to a puncture eventually done in seconds. That they nevertheless find proponents marks the aversion to puncture as a very individual problem. The retrograde technique with modifications is not expected to become a serious competitor to antegrade procedures.

Another retrograde technique is the so-called endoscopic-guided access (EGA). The tip of a flexible scope in the selected access calyx can serve as target for FP or UP in a 'seeing is believing' procedure. The puncture is not in fact guided, only the moment the needle enters the collecting system is seen [36].

A microfibre optic inserted in the puncture needle and coupled to a camera was sold as the 'all seeing needle' in 2011. It was advertised as 'making fluoroscopy monitoring dispensable', which it does not. Just as in UARN, terms like 'endoscopic' or 'optical puncture' are misleading, as only the successful endpoint of the puncture is truly visible. All views

of the other areas of the needle's path are of questionable value, as shown in the need for an arterial embolisation to deal with a complication in one report.

A step forward in this technique is to replace the optical control by an optical coherence tomography (OCT) endoscopic system. The tissue ahead of the needle was clearly distinguished as renal cortex, medulla, or calyx in animal experiments [38]. Robot-assisted puncture systems already evaluate this technique.

Two studies have dispensed with retrograde manipulations. In a RCT, a double-needle technique with an antegrade air pyelogram saved 25 min of access time [30]. UP of dilated collecting systems can be performed without retrograde pyelography, a routine in my early cases (Fig. 1) [6]. In addition, stones in calyces are easy targets for UP.

Combined URS plus PNL is a popular procedure. Seeing the needle entering the collecting system may be used more frequently to confirm the correct puncture, especially in UP of non-dilated systems.

Virtual Imaging, 3-D Image Reconstruction

The CT-based 3-D images are used for strategic planning of PNL and, in combination with other techniques, to guide the puncture. C-arm cone-beam CT comes closest to intraoperative 3-D real-time imaging and small series' results are good. In the largest series, the complex setting, and a competitive 98.8% success rate of UP was the reason it was chosen only in a highly selected 6.5% of cases requiring a percutaneous access [39].

Fusion of 3-D reconstructed CT images with US produced impressive images. The improved first-pass puncture rate (98.41% vs UP 81.82%) was probably generated at the expense of very high radiation exposure [40]. The inclusion of preoperatively generated CT- or MRI-based images in actual procedures suffers from the fact that they cannot offer real-time orientation during the puncture. Used during PNL, the target in the stored images is often projected as close to the real target as a slightly failed standard puncture. There is ongoing highly interesting research in the field of intraoperative fusion of stored images and real-time US [41].

Electromagnetic and Optical Tracking

Preliminary clinical results with three different electromagnetic tracking (EMT) puncture systems have been published.

Using EM sensors in the needle and on the US probe, the needle and its predicted path are virtually displayed on a screen as long as they are within the selected scanning plane showing the target. An advantage is the easy set-up. One of

the limits is the quality of the US image, which varies with BMI.

The most elaborate set-up uses URS to place a ureteric catheter with a sensor tip in the target calyx. This sensor and one at the tip of the puncture needle are schematically displayed on a screen. With the flexible scope in place, the successful access in the collecting system is seen on a separate video screen [42]. EMT is a fast-growing technique in various medical fields and news for PNL will come.

Optical tracking was evaluated in a bench-top model. Different from EMT, only the outer part of the needle can be tracked and used to predict the needle's path, which is simulated on the US screen. However, needles bend inside the patient and do not follow the projected path [43], a problem that applies to all puncture techniques.

Needle Guiding, Hands and Needles

The visibility of needles is different for FP and UP. With FP, the needle is only visible during fluoroscopy. Deviations from the planned course are noticed relatively late when they are displayed in another plane or when the tip misses the target. With UP, needle echoes disappear in real time, the moment the needle appears to leave the scanning plane. This also often happens with needle guide adapters or echo-tip needles. A technical problem not discussed in the PNL literature.

An UP can be performed in the scan plane (longitudinal) from the narrow side of the probe where the needle guide adapter is usually mounted, or laterally, perpendicular to the transducer, outside the scan plane (transversal). With the latter technique, it is not necessary or possible to follow the

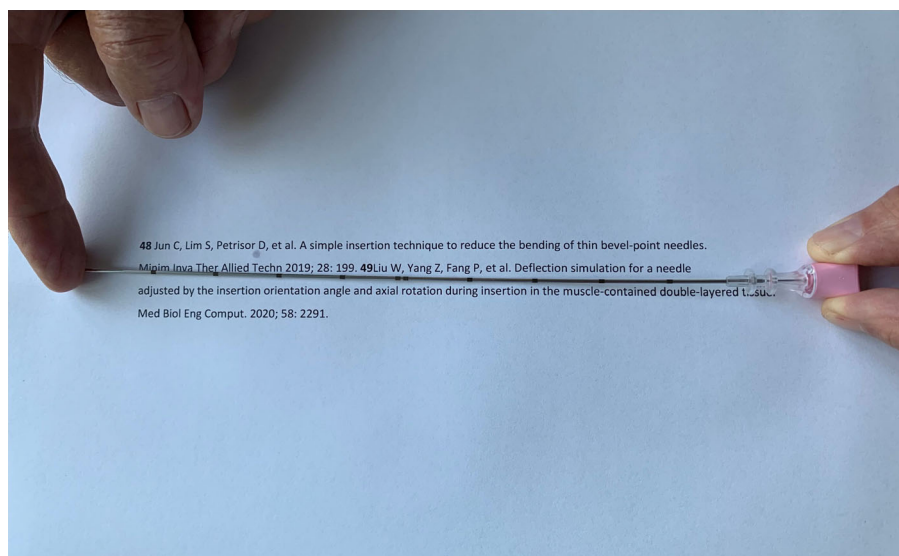
path of the needle. The needle echo becomes visible only once when the needle crosses the scanning plane in the target area. In a small series, the puncture time and the one-puncture success rate with the transversal technique were superior to those of the longitudinal approach [24]. The accompanying hypotheses are somewhat fanciful. However, provided a non-papillary approach is also accepted, the technique may offer relief from the constraint of having to follow the needle completely and continuously in the scan. Transversal needle guide adaptors are available and have been modified by anaesthetists for a safe puncture [44].

Needle visibility is not the only problem. If all PNL steps are performed under US control (UPNL), stable imaging planes or easily controllable stepwise changes are needed. The many simultaneous tasks can overwhelm the examiner: manipulating the US transducer and the needle, looking at the screen for needle echoes and rocking the transducer to find the needle echoes or to maintain the scanning plane, while dilatating the tract. The optimal scanning plane is easily lost, and more than two hands may be needed, which is well seen in a video [45]. An articulated arm [46] or at least a 'gooseneck' arm, as already described by anaesthetists in 2006 could give stable imaging conditions [47].

Why do needles not hit the target on the first pass? Why are there second and third puncture attempts? The first-pass success rate varies between <58% to 100% [42], which may also be due to bias when introducing new techniques.

The most commonly used, cheap Chiba needle finds its own way and can deviate from the planned path by 1–2 cm [48,49]. The bevelled tip of the needle acts like a ruder and deflects the needle tip, causing it to leave the path. With

Figure 2 Minimal forces are sufficient to bend a standard 18-G percutaneous access needle. The instructions for use do not mention bending of the needle as an adverse event



symmetrical-shaped needle tips, the bending is less pronounced. However, the resistance forces of the tissue are not symmetrical and additionally lead to misalignment (Fig. 2). The wrong angle is maintained and the distance to the target increases continuously as the needle advances. For bevelled needles, rotation of the needle by 180° at an insertion depth that depends on the needle size and the depth of the target is recommended to bring the needle back on course [48]. Needle deviation is independent of the guiding technique. In the urological literature, needle bending is rarely mentioned as a possible puncture problem [43]. In all, 85% of interventional radiologists experienced unwanted needle bending [50]. Many anaesthesiological, radiological and technical reports have discussed this problem and even led to the design of steerable needles. Urology is only marginally concerned with needle problems that are realised during prostate biopsies or seed implantations. To understand the possibilities and limitations of UP, 'Ultrasound-guided needle insertion robotic system for percutaneous puncture' [46] is an actual must-read.

CONCLUSION

Imaging for and guidance of the puncture receives continuous attention in recent literature.

Modifications continue to appear. Reduction of radiation is the most frequently evaluated effect. Time to establish a proper access or number of needle passes are more sporadically reported. There are no standards to measure type and number of puncture mistakes or quality of the access, although they could contribute most to better understanding, education, and patient safety. Disciplines other than urology are more concerned with the problems and development of puncture. The important change in recent years is the wide acceptance of US as the leading imaging technique.

Conflicts of Interest

None declared.

References

- Zhu W, Li J, Yuan J et al. A prospective and randomised trial comparing fluoroscopic, total ultrasonographic and combined guidance for renal access in mini-percutaneous nephrolithotomy. *BJU Int* 2017; 119: 612–8.
- Breda A, Territo A, Scoffone C et al. The evaluation of radiologic methods for access guidance in percutaneous nephrolithotomy: a systematic review of the literature. *Scand J Urol* 2018; 52: 81–6.
- Hajiha M, Baldwin DD. New technologies to aid in percutaneous access. *Urol Clin North Am* 2019; 46: 225–43.
- Nguyen DD, Luo JW, Tailly T, Bhojani N. Percutaneous nephrolithotomy access: a systematic review of intraoperative assistive technologies. *J Endourol* 2019; 33: 358–68.
- Corrales M, Doizi S, Barghouthy Y, Kamkour H, Somani B, Traxer O. Ultrasound or fluoroscopy for percutaneous nephrolithotomy access, is there really a difference? A review of literature. *J Endourol* 2021; 35: 241–8.
- Alken P. History of PNL. In Zeng G, Sarica K eds, *Percutaneous Nephrolithotomy*. Singapore: Springer Nature, 2020: 1–12.
- Armitage JN, Withington J, Fowler S et al. BAUS section of Endourology. Percutaneous nephrolithotomy access by urologist or interventional radiologist: practice and outcomes in the UK. *BJU Int* 2017; 119: 913–8. <https://doi.org/10.1111/bju.13817>
- Basiri A, Shakiba B, Hoshyar H, Ansari A, Golshan A. Biplanar oblique access technique: A new approach to improve the success rate of percutaneous nephrolithotomy. *Urologia* 2018; 85: 118–22.
- Hosseini MM, Yousefi A, Rastegari M. Pure ultrasonography-guided radiation-free percutaneous nephrolithotomy: report of 357 cases. *Springerplus*. 2015; 4: 313.
- Basiri A, Kashi AH, Zeinali M, Nasiri M, Sarhangnejad R, Valipour R. Ultrasound - guided access during percutaneous nephrolithotomy: entering desired calyx with appropriate entry site and angle. *Int Braz J Urol* 2016; 42: 1160–7.
- El-Shaer W, Kandeel W, Abdel-Lateef S, Torky A, Elshaer A. Complete ultrasound-guided percutaneous nephrolithotomy in prone and supine positions: a randomized controlled study. *Urology* 2019; 128: 31–7.
- Hazir B, Citamak B, Asci A et al. Changes in percutaneous approach to kidney stones in children: A single institute experience over 500 cases. *Int J Clin Pract* 2021; 22: e14243.
- Kim HY, Lee KW, Lee DS. Critical causes in severe bleeding requiring angioembolization after percutaneous nephrolithotomy. *BMC Urol* 2020; 20: 22.
- Kallidonis P, Vagionis A, Vrettos T et al. Non papillary mini-percutaneous nephrolithotomy: early experience. *World J Urol* 2021; 39: 1241–6.
- Ozgor F, Tepeler A, Basibuyuk I. Supracostal access for miniaturized percutaneous nephrolithotomy: comparison of supracostal and infracostal approaches. *Urolithiasis*. 2018; 46: 279–83.
- He Z, Tang F, Lu Z et al. Comparison of supracostal and infracostal access for percutaneous nephrolithotomy: a systematic review and meta-analysis. *Urol J*. 2019; 16: 107–14.
- Knoll T, Michel MS, Alken P. Surgical Atlas. Percutaneous nephrolithotomy: the Mannheim technique. *BJU Int* 2007; 99: 213–31.
- Pulido-Contreras E, Garcia-Padilla MA, Medrano-Sanchez J, Leon-Verdin G, Primo-Rivera MA, Sur RL. Percutaneous nephrolithotomy with ultrasound-assisted puncture: does the technique reduce dependence on fluoroscopic ionizing radiation? *World J Urol* 2021. <https://doi.org/10.1007/s00345-021-03636-2>
- Jaipuria J, Suryavanshi M, Desai AP et al. Stepwise case selection using Guy's stone score reduces complications during percutaneous nephrolithotomy training. *Indian J Urol*. 2017; 33: 41–7.
- Yu W, Rao T, Li X et al. The learning curve for access creation in solo ultrasonography-guided percutaneous nephrolithotomy and the associated skills. *Int Urol Nephrol* 2017; 49: 419–24.
- Bayne DB, Usawachintachit M, Tzou D, Taguchi K, Shindel A, Chi TL. Increasing body mass index steepens the learning curve for ultrasound-guided percutaneous nephrolithotomy. *Urology* 2018; 120: 68–73.
- Sharma GR, Luitel B. Techniques for fluoroscopy-guided percutaneous renal access: An analytical review. *Indian J Urol*. 2019; 35: 259–66.
- Fan D, Song L, Li M et al. Study on clinical application of different ultrasound-guided planar techniques in minimally invasive percutaneous nephrolithotomy. *Surg Innov*. 2021 [Online ahead of print]. DOI: <https://doi.org/10.1177/1553350621997795>.
- Noureddin YA, Andonian S. Simulation for percutaneous renal access: where are we? *J Endourol* 2017; 31: S10–9.
- Sainsbury B, Łacki M, Shahait M et al. Evaluation of a virtual reality percutaneous nephrolithotomy (PCNL) surgical simulator. *Front Robot AI*. 2020; 6: 145. <https://doi.org/10.3389/frobt.2019.00145>
- Bheri MM. Estimating the depth of puncture in percutaneous nephrolithotomy: an alternative approach. *Br J Urol* 1998; 81: 620–1.

- 27 Bilen CY, Aşçı R, Sarıkaya S, Büyükalpelli R, Yılmaz AF. Laser-assisted fluoroscopic puncture: a new technique for accessing the kidney. *J Endourol* 2003; 17: 485–91
- 28 Oo MM, Gandhi HR, Chong KT et al. Automated Needle Targeting with X-ray (ANT-X) - Robot-assisted device for percutaneous nephrolithotomy (PCNL) with its first successful use in human. *J Endourol* 2021; 3: e919
- 29 Gupta P, Choudhary GR, Pandey H, Madduri VKS, Singh M, Pallagani L. Air vs contrast pyelogram for initial puncture access in percutaneous nephrolithotomy: a randomized controlled trial. *Urolithiasis*. 2021; 49: 261–7
- 30 Jangid DK, Sharma G, Yadav SS, Tomar V, Mathur R. A Comparative Study of Antegrade Air Pyelogram and Retrograde Air Pyelogram for Initial Puncture Access during Percutaneous Nephrolithotomy. *J Clin Diagn Res*. 2017; 11: PC01–3
- 31 Liu Q, Zhou L, Cai X, Jin T, Wang K. Fluoroscopy versus ultrasound for image guidance during percutaneous nephrolithotomy: a systematic review and meta-analysis. *Urolithiasis*. 2017; 45: 481–7
- 32 Hong Y, Xu Q, Huang X, Zhu Z, Yang Q, An L. Ultrasound-guided minimally invasive percutaneous nephrolithotomy in the treatment of pediatric patients <6 years: A single-center 10 years' experience. *Medicine (Baltimore)*. 2018; 97: e0174
- 33 Wang S, Zhang X, Xiao B, Hu W, Chen S, Li J. Ultrasound-guided percutaneous nephrolithotomy for upper urinary tract calculi in patients with spinal deformity: a decade's experience. *BJU Int* 2019; 124: 109–15
- 34 Armas-Phan M, Tzou DT, Bayne DB, Wiener SV, Stoller ML, Chi T. Ultrasound guidance can be used safely for renal tract dilatation during percutaneous nephrolithotomy. *BJU Int* 2020; 125: 284–91
- 35 Sun H, Zhang Z, Huang G et al. Fluoroscopy versus ultrasonography guided mini-percutaneous nephrolithotomy in patients with autosomal dominant polycystic kidney disease. *Urolithiasis*. 2017; 45: 297–303
- 36 Alsayouf M, Arenas JL, Smith JC et al. Direct endoscopic visualization combined with ultrasound guided access during percutaneous nephrolithotomy: a feasibility study and comparison to a conventional cohort. *J Urol* 2016; 196: 227–33
- 37 Kaler KS, Parkhomenko E, Okunohov Z et al. Ureteroscopic holmium laser-assisted retrograde nephrostomy access: a novel approach to percutaneous stone removal. *World J Urol* 2018; 36: 963–9
- 38 Wang C, Calle P, Tang Q et al. Deep-learning-aided forward optical coherence tomography endoscope for percutaneous nephrostomy guidance. *Biomed. Opt Express* 2021; 12: 2404–18. <https://doi.org/10.1364/BOE.421299>
- 39 Hawkins CM, Kukreja K, Singewald T et al. Use of cone-beam CT and live 3-D needle guidance to facilitate percutaneous nephrostomy and nephrolithotripsy access in children and adolescents. *Pediatr Radiol* 2016; 46: 570–4
- 40 Xu Z, Li Z, Guo M, Bian H, Niu T, Wang J. Application of three-dimensional visualization fused with ultrasound for percutaneous renal puncture. *Sci Rep* 2021; 11: 8521
- 41 Gomes-Fonseca J, Queirós S, Morais P et al. Surface-based registration between CT and US for image-guided percutaneous renal access - A feasibility study. *Med Phys* 2019; 46: 1115–26
- 42 Lima E, Rodrigues PL, Mota P et al. Ureterscopy-assisted percutaneous kidney access made easy: first clinical experience with a novel navigation system using electromagnetic guidance (IDEAL Stage 1). *Eur Urol* 2017; 72: 610–6
- 43 Thomas A, Ewald J, Kelly I et al. Conventional vs computer-assisted stereoscopic ultrasound needle guidance for renal access: a randomized crossover bench-top trial. *J Endourol* 2018; 32: 424–30
- 44 Neice AE, Forton C. Evaluation of a novel out-of-plane needle guide. *J Ultrasound Med* 2018; 37: 543–9
- 45 Tzou DT, Metzler IS, Usawachintachit M, Stoller ML, Chi T. Ultrasound-guided access and dilation for percutaneous nephrolithotomy in the supine position: a step-by-step approach. *Urology* 2019; 133: 245–6
- 46 Chen S, Wang F, Lin Y, Shi Q, Wang Y. Ultrasound-guided needle insertion robotic system for percutaneous puncture. *Int J Comput Assist Radiol Surg* 2021; 16: 475–84
- 47 Chapman GA, Johnson D, Bodenham AR. Visualisation of needle position using ultrasonography. *Anaesthesia* 2006; 61: 148–58
- 48 Jun C, Lim S, Petrisor D, Chirikjian G, Kim JS, Stoianovici D. A simple insertion technique to reduce the bending of thin bevel-point needles. *Minim Invasive Ther Allied Technol* 2019; 28: 199–205
- 49 Liu W, Yang Z, Fang P, Jiang S. Deflection simulation for a needle adjusted by the insertion orientation angle and axial rotation during insertion in the muscle-contained double-layered tissue. *Med Biol Eng Comput*. 2020; 58: 2291–304
- 50 de Jong TL, van de Berg NJ, Tas L, Moelker A, Dankelman J, van den Dobbelsteen JJ. Needle placement errors: do we need steerable needles in interventional radiology? *Med Devices (Auckl)*. 2018; 11: 259–65

Correspondence: Peter Alken, Department of Urology, Klinik für Urologie und Urochirurgie, Universitätsmedizin Mannheim, Theodor-Kutzer-Ufer 1-3, 68167 Mannheim, Germany.

e-mail: Peter.alken@medma.uni-heidelberg.de

Abbreviations: BMI, body mass index; (2-)(3-)D, (two-)(three-)dimensional; EMT, electromagnetic tracking; FA, fluoroscopic access; FP, fluoroscopic-guided puncture; FPNL, fluoroscopic PNL; FUA, fluoroscopic and US access; FUP, combined fluoroscopic and US-guided puncture; FUPNL, fluoroscopic and US PNL; OR, operating room; PNL, percutaneous nephrolithotomy; RCT, randomised controlled trial; UA, US access; UARN, URS-assisted retrograde nephrostomy; UP, US-guided puncture; UPNL, US PNL; URS, ureteroscopy; US, ultrasonography/ultrasonographic.