World Journal of Urology (2026) 44:724
https://doi.org/10.1007/s00345-026-06831-1

RESEARCH

Partial vs. whole-gland salvage hifu after radiotherapy failure: oncological and functional outcomes

Cyriel Maillard[1] · Samy Mebroukine[1] · Thibaud Haaser[2] · Gilles Pasticier[3] · Grégoire Robert[1] · Franck Bladou[1]

Received: 16 May 2026 / Accepted: 22 September 2026
© The Author(s), under exclusive licence to Springer-Verlag GmbH Germany, part of Springer Nature 2026

Abstract

Purpose To evaluate the long-term oncological and functional outcomes of whole-gland and partial-gland salvage high-intensity focused ultrasound (S-HIFU) in patients with radiorecurrent prostate cancer, for whom local recurrence after radiotherapy remains a major therapeutic challenge and radical salvage surgery is associated with substantial morbidity.

Methods We performed a retrospective single-center study including 138 patients treated with S-HIFU between August 2006 and October 2023 for biopsy-proven local recurrence without metastatic disease. Treatments consisted of whole-gland or partial-gland ablation, including hemi-gland and focal therapy. Oncological outcomes were assessed using Kaplan–Meier analyses and multivariable Cox regression models evaluating progression-free survival (PFS), metastasis-free survival (MFS), and cancer-specific survival (CSS). Postoperative complications were graded according to the Clavien–Dindo classification.

Results After a median follow-up of over five years, 5-year PFS, MFS, and CSS rates were 43.6%, 85%, and 95%, respectively. Higher pre-HIFU prostate-specific antigen (PSA) levels and ISUP grade ≥ 5 independently predicted disease progression. No significant differences in PFS or MFS were observed between whole-gland and partial-gland treatments. Acute urinary retention occurred in 33% of patients and voiding dysfunction in 39.9%, requiring surgical management in 34.1% of cases. Severe complications were significantly more frequent after whole-gland compared with partial-gland S-HIFU (48.3% vs. 29.8%, $p < 0.05$).

Conclusion S-HIFU represents a viable salvage option after radiotherapy failure. Our results support that partial-gland S-HIFU significantly reduces severe morbidity while maintaining comparable oncological outcomes compared to whole-gland S-HIFU in appropriately selected patients.

Keywords Ablation techniques · High-intensity focused ultrasound ablation · Prostatic neoplasms · Radiotherapy · Salvage therapy · Treatment outcome

Introduction

Prostate cancer (PCa) remains one of the main causes of cancer-related mortality among men worldwide. External beam radiotherapy (EBRT) and brachytherapy are widely employed as first-line curative treatments. However, approximately one third of patients will experience biochemical recurrence within 5 to 10 years [1].

According to the European Association of Urology (EAU) guidelines, therapeutic options for radiorecurrent prostate cancer include salvage local procedures such as radical prostatectomy, re-irradiation, cryotherapy, or HIFU as well as androgen deprivation therapy or active surveillance. Five-year recurrence-free survival ranges from approximately 50% to 60% across modalities, with no consensus recommendation currently favoured for any single modality given the low quality of available evidence [2, 3].

Historically, salvage radical prostatectomy (SRP) was associated with significant morbidity, including urinary incontinence, erectile dysfunction, and rectal injury [4]. Consequently, many patients are managed with androgen

✉ Samy Mebroukine
samy.mebroukine@chu-bordeaux.fr

1 Department of Urology, Bordeaux University Hospital, Place Amélie Raba Léon, Bordeaux 33000, France

2 Department of Radiation Oncology, Bordeaux University Hospital, Bordeaux, France

3 Department of Urology, Clinique Tivoli, Bordeaux, France

Published online: 05 October 2026

deprivation therapy (ADT), which remains palliative and may lead to potential long-term adverse effects, or placed under active surveillance [5, 6].

For the past few years, less invasive local salvage strategies have gained increasing interest. Among them, high-intensity focused ultrasound (HIFU) has emerged as a promising alternative. HIFU uses precisely focused acoustic energy to thermally ablate malignant tissue while preserving surrounding structures. Salvage HIFU (S-HIFU) can be administered using different approaches: as whole-gland (total) ablation, targeting the entire prostate, or as hemi-gland ablation (hemi-HIFU), selectively treating the affected lobe in cases of unilateral disease. More recently, focal therapy has also been proposed for selected cases.

While oncological outcomes of S-HIFU appear encouraging, with five-year progression-free survival (PFS) rate ranging from 40% to 50% and overall survival reaching up to 85% [7], the heterogeneity of treatment techniques and patient selection criteria limits generalizability. Additionally, functional outcomes, particularly urinary and rectal complications, vary depending on the extent of ablation. Comparative assessments of whole-gland and partial gland S-HIFU approaches are therefore necessary to better define their respective indications and safety profiles.

The aim of this study was to assess the oncological and functional outcomes of S-HIFU in a large, single-center cohort of patients with localized prostate cancer recurrence following radiotherapy and compared whole-gland versus partial gland S-HIFU outcomes.

Patients and methods

Study design and population

We conducted a retrospective study screening all patients who underwent salvage high-intensity focused ultrasound (S-HIFU) at Bordeaux University Hospital between August 2006 and October 2023. Only those treated for local recurrence of prostate cancer following external beam radiotherapy (EBRT) as primary radiation treatment were included. Local recurrence was defined as a rise in PSA according to the Phoenix definition (PSA nadir+2 ng/mL) and/or positive prostate biopsies, without radiographic evidence of metastatic disease on restaging (PET-CT or CT TAP with bone scan).

The choice of S-HIFU was made following multidisciplinary discussion in all cases, considering patient preference, clinical eligibility, and individual risk-benefit assessment. Some patients were considered unsuitable for surgery or re-irradiation, while others specifically opted for a less invasive approach. Patients whose procedures were interrupted for technical or medical reasons or with follow-up <6 months were excluded. Both in-house and patients referred by urologists from southwestern France were included. This study was approved by the local ethics committee (approval number CER-BDX 2026-34). Patients were informed and included under a non-opposition procedure in accordance with national data protection regulations.

Treatment procedure

Between 2006 and 2015, procedures were performed using the Ablatherm® system (EDAP-TMS, France), and from 2015 onwards with the Focal One® platform (EDAP-TMS, France). All treatments were delivered in a single session under general anesthesia, usually in an outpatient setting. Patients with anal stenosis, rectal wall thickness>6 mm on intraoperative ultrasound — assessed to minimise the risk of rectourethral fistula — or intraoperative HIFU system malfunction preventing safe treatment delivery were not treated and excluded. Treatment modalities included whole-gland (total S-HIFU), hemi-gland (hemi-S-HIFU), or focal ablation, based on tumor laterality and disease characteristics. Partial-gland S-HIFU was selected based on disease laterality and biopsy findings: hemi-gland ablation was performed in patients with unilateral disease confirmed by positive biopsies limited to one lobe, with or without concordant MRI findings — as multiparametric MRI was not systematically available throughout the entire study period — while focal ablation was reserved for patients with a single MRI-visible target lesion and no additional positive biopsy cores elsewhere in the gland. Whole-gland ablation was performed in cases of bilateral disease or when laterality could not be established.

In selected cases, cervico-prostatic incision or transurethral resection of the prostate (TURP) were performed intraoperatively, based on prostate size or voiding symptoms. Intraoperative TURP or cervico-prostatic incision and urinary events occurring during the catheterisation period were not recorded as complications. Catheterization duration was tailored by the operator. Four experienced surgeons performed all procedures in a center averaging with more than 20 HIFU cases annually. Incomplete treatment was defined as any procedure in which the full planned ultrasound treatment programme could not be delivered, due to intraoperative anatomical constraints, patient tolerance, inability to complete the full sequence of planned ultrasound shots, or failure to achieve complete coverage of the intended treatment zone.

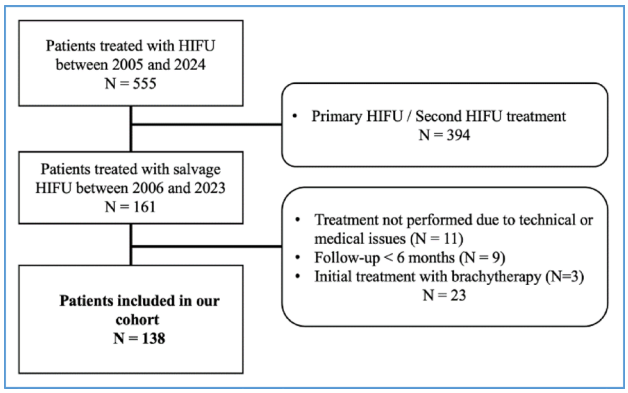

Fig. 1 Flow Chart

Table 1 Population characteristics

Characteristics	Whole–gland HIFU (*N*=89)	Partial S–HIFU (*N*=49)	*p*–value
Median PSA at EBRT (ng/mL)	11 (8, 15)	9 (7, 20)	0.8
ISUP score before EBRT:			0.8
1	43 (48%)	20 (41%)	
2	24 (27%)	17 (35%)	
3	17 (19%)	9 (18%)	
4	4 (4.5%)	2 (4.1%)	
5	1 (1.1%)	1 (2.0%)	
D'Amico risk group before EBRT:			0.8
Low	25 (28%)	12 (24%)	
Intermediate			
Favorable	34 (38%)	18 (37%)	
Unfavorable	10 (11%)	5 (10%)	
High	20 (22%)	14 (29%)	
Median age at EBRT (years)	65 (61, 70)	68 (63, 71)	0.040
Median PSA nadir after EBRT (ng/mL)	0.32 (0.07, 0.77)	0.43 (0.09, 0.90)	0.8
Prior androgen deprivation therapy			>0.9
No	35 (39%)	18 (38%)	
Yes			
Short (≤6 months)	22(25%)	13 (28%)	
Long (>6 months)	32 (36%)	16 (34%)	
Unknown	0	2 (4.1%)	
Median age at S–HIFU (years)	71 (67, 76)	75 (70, 78)	0.005
Median interval between EBRT and S–HIFU (years)	5 (4, 8)	7 (5, 9)	0.063
Median PSA at S–HIFU (ng/mL)	3.9 (3.0, 6.2)	4.4 (2.9, 6.5)	0.6
Median prostate volume at S–HIFU (cm^3)	19 (15, 24)	25 (20, 32)	<0.001

Outcomes and follow-up

Patients were reviewed at 3- and 6-months post-procedure with PSA concentration. Thereafter, annually with referring urologists. Control biopsies were not systematic. Disease progression was defined as a composite endpoint: PSA > nadir + 2 ng/mL (Phoenix definition) [8], or initiation of androgen deprivation therapy, or positive control biopsies. Patients initially treated with partial gland S-HIFU (hemi-gland or focal S-HIFU) were eligible for repeat treatment in case of recurrence in untreated zones. Functional outcomes were based on urologist's clinical reports. Erectile function was not analyzed due to inconsistent documentation. Postoperative complications were graded using the Clavien-Dindo classification [9].

Statistical analysis

Data analysis was performed using R software version 4.3.2 (Urbanek & H.-J. Bibiko, © R Foundation for Statistical Computing, 2023). The statistical significance threshold was set at 0.05 for all statistical tests, and p-values were two-sided. Categorical data were expressed as percentages and compared using the chi-squared test. Normality of quantitative variables was assessed using the Shapiro-Wilk test. As the majority of variables significantly deviated from normal distribution, quantitative data were expressed as medians and interquartile ranges (IQR) and compared using the Wilcoxon rank-sum test as a non-parametric approach for all quantitative comparisons. PFS, MFS, CSS, and OS were analyzed using Kaplan-Meier curves, log-rank tests, and Cox regression analyses. Multivariate Cox models for PFS and MFS were conducted after verifying deviance and proportionality assumptions.

Results

Population characteristics

Our study population initially included 555 patients who underwent HIFU, of whom 138 met the predetermined inclusion criteria (Fig. 1). Baseline characteristics are summarized in Table 1. The median age at S-HIFU was 72 years (IQR 68–77), and the median pre-HIFU PSA was 4.1 ng/mL (IQR 3.0–6.2). Eighty-three patients (61%) had received prior androgen deprivation therapy (ADT) during EBRT, including 35 (26%) with short-term (≤6 months) and 48 (35%) with long-term (≥6 months) ADT. The median interval between EBRT and S-HIFU was 6 years (IQR 4–9).

Eighty-nine patients (64.5%) underwent a whole gland S-HIFU: including 70 patients (50.7%) with a complete gland coverage treatment and 19 (13.8%) with a subtotal bilateral ablation. Forty-nine patients (35,5%) underwent a partial S-HIFU including hemi-gland S-HIFU in 45 patients (32.6%), and focal ablation in 4 patients (2.9%). Focal ablation procedure targeted MRI-visible lesions with

index positive biopsies. Incomplete treatment occurred in 14 (10.1%) cases. The median post-HIFU PSA nadir was 0.33 ng/mL (IQR 0.075–1.75).

Oncological outcomes

The median follow-up was 61.5 months (IQR 30–107). Disease progression occurred in 76 patients (55%) and 34 (24.6%) patients developed metastatic disease. Seventeen patients (12.3%) died from prostate cancer. Nine patients (6.5%) underwent a second S-HIFU due to early local recurrence in untreated zones. One patient subsequently underwent SRP.

ADT was initiated in 66 patients (47.8%) following progression: as monotherapy in 60 (44%) and combined with salvage interventions in 6 (4.3%) — including second S-HIFU ($n=5$) and SRP ($n=1$).

Five-year cancer-specific survival (CSS), metastasis-free survival (MFS), and progression-free survival (PFS) were 95% (95% CI, 90.7–99.5), 85% (95% CI, 78.5–92.3), and 43.6% (95% CI, 35.2–54.1), respectively. Ten-year, CSS, MFS, and PFS were 80% (95% CI, 70.2–91.1), 60.3% (95% CI, 49.2–73.9), and 31.2% (95% CI, 22.3–43.6), respectively (Fig. 2).

Univariate and multivariable Cox regression analyses for PFS and MFS are presented in Table 2 and Supplementary Table 1 respectively.

On multivariable analysis, several factors were independently associated with disease progression. A longer interval between EBRT and S-HIFU was associated with a lower risk of progression (HR 0.92; 95% CI, 0.84–0.99; $p=0.04$). In contrast, a higher post-S-HIFU PSA nadir was associated with an increased risk of progression (HR 1.38; 95% CI, 1.27–1.49; $p<0.001$). Incomplete treatment was also associated with a higher risk of progression (HR 3.86; 95% CI, 1.99–7.47; $p<0.001$), as was ISUP 5 disease (HR 3.32; 95% CI, 1.31–8.38; $p=0.01$).

Regarding metastatic progression, ISUP 5 tumors prior to S-HIFU were associated with a significantly increased risk of metastasis (HR 2.62; 95% CI, 1.06–6.49; $p=0.04$). Incomplete treatment was likewise associated with a higher risk of metastatic progression (HR 3.33; 95% CI, 1.74–6.38; $p=0.001$), as was a higher post-S-HIFU PSA nadir (HR 1.39; 95% CI, 1.29–1.51; $p<0.001$).

Comparison between whole-gland and partial gland S-HIFU revealed no significant difference in PFS (medians: 44 months vs. 35 months, $p=0.56$) or MFS (medians: 159 months vs. not reached $p=0.69$) (Fig. 3).

Fig. 2 Kaplan-Meyer survival curve for PFS **A** and MFS **B**

S-HIFU adverse events

Concerning postoperative adverse events, shown in Supplementary Fig. 1, Acute urinary retention requiring catheterization occurred in 46 patients (33.3%). Severe voiding dysfunction appeared in 55 patients (39.9%), attributed either to isolated fossa sclerosis (21.0%), isolated urethral strictures (7.2%) or both (5.8%), and necessitated endoscopic surgical management in 47 (34,1%) cases. Four patients (2.9%) ultimately required a palliative non-continent urinary diversion after endoscopic treatment failure.

Urinary incontinence was reported in 33 patients (23.9%), including one patient who required implantation of an artificial urinary sphincter. Rectourethral fistula occurred in four patients (2.9%): two were managed conservatively with prolonged urethral or suprapubic catheterization, while two required urinary diversion. Additionally, three patients (2.2%) developed pubic osteitis; one was managed with urinary diversion and the remaining two with long-term antibiotic therapy.

No difference was found between whole gland S-HIFU and partial gland S-HIFU concerning all adverse events (67.4% vs. 70.2%, $\chi^2 = 0.11$, $p=0.74$). However, severe complications (Clavien-Dindo grade≥3) were more frequent after whole-gland S-HIFU compared with partial gland S-HIFU (48.3% vs. 29.8%, $\chi^2 = 4.34$, $p=0.04$).

Discussion

Context and findings

The optimal management of radiorecurrent prostate cancer remains debated. According to the EAU guidelines, SRP, brachytherapy, and Stereotactic Body Radiation Therapy (SBRT) are strongly recommended in experienced centres for patients with biopsy-proven local recurrence seeking curative intent, whereas S-HIFU and cryoablation carry only a weak recommendation, reserved for highly selected patients within a clinical trial setting or well-designed prospective cohort [2].

While SRP has demonstrated robust oncological outcomes — with over 70% metastasis-free survival at 10 years and a 5-year PFS of approximately 47%— it is associated with substantial morbidity, with major complications (Clavien-Dindo grade ≥ 3) reported in up to 64% of cases [2, 4, 10]. Re-irradiation techniques achieve five-year Biochemical recurrence (BCR)-free survival rates of 56–60% with a more favourable toxicity profile and severe genitourinary toxicity below 8% for both brachytherapy and SBRT

PFS

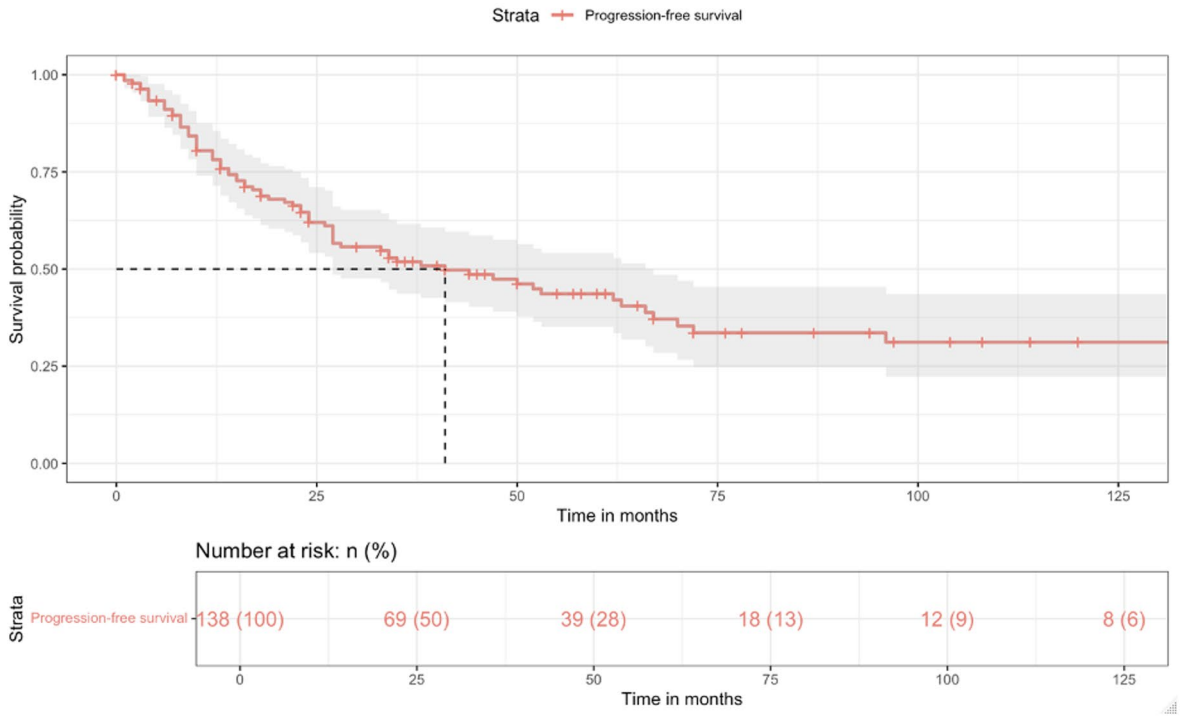
Strata
Progression-free survival
Survival probability
1.00
0.75
0.50
0.25
0.00
0
25
50
75
100
125
Time in months
Number at risk: n (%)
Strata
Progression-free survival
138 (100)
69 (50)
39 (28)
18 (13)
12 (9)
8 (6)
Time in months

MFS

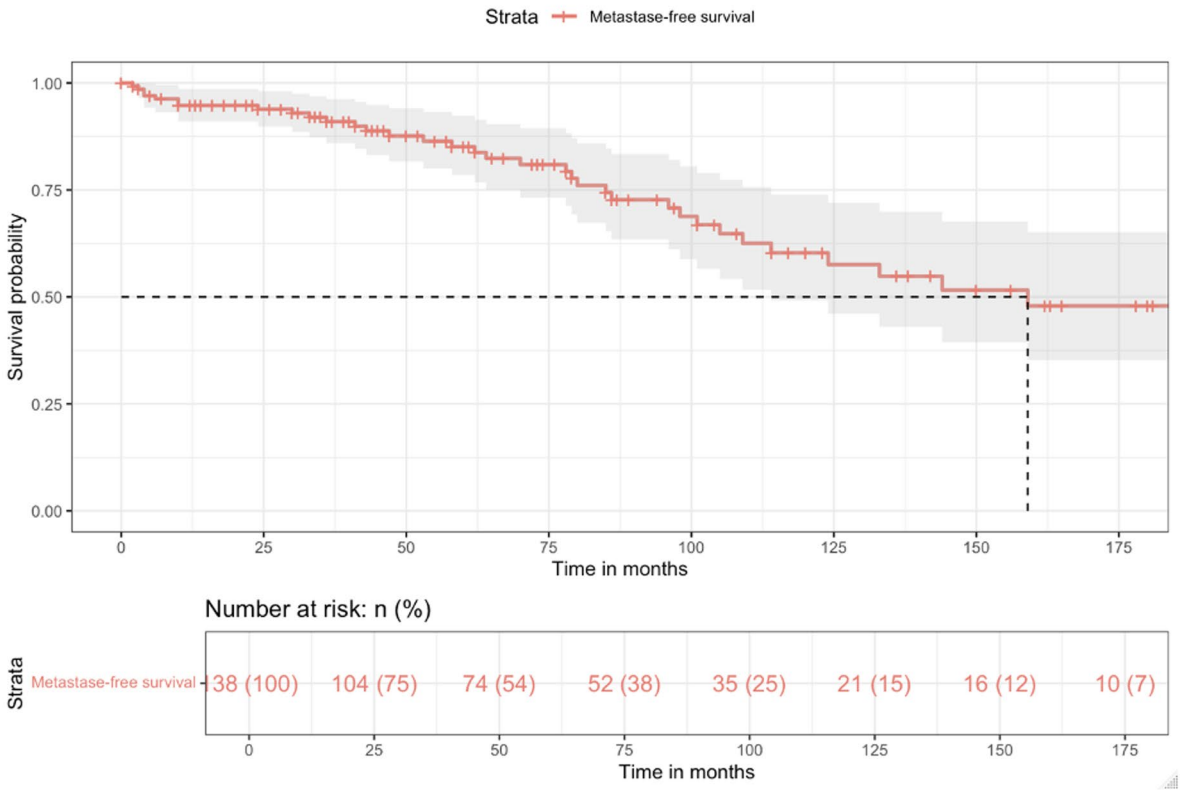
Strata
Metastase-free survival
Survival probability
1.00
0.75
0.50
0.25
0.00
0
25
50
75
100
125
150
175
Time in months
Number at risk: n (%)
Strata
Metastase-free survival
138 (100)
104 (75)
74 (54)
52 (38)
35 (25)
21 (15)
16 (12)
10 (7)
Time in months

Table 2 Univariate and multivariate Cox regression for progression-free survival

	Univariate Analysis – PFS			Multivariate Analysis – PFS		
	HR	95% CI	*p*–value	HR	95% CI	*p*–value
pre–RT PSA	1.013	0.99–1.033	0.2	–	–	–
pre–RT ISUP Grade				–	–	–
1	Ref	–	–	–	–	–
2	0.98	0.57–1.71	0.95			
3	1.44	0.79–2.65	0.23			
4	2.23	0.87–7.5.73	0.09			
5	1.67	0.23–12.31	0.62			
Pre–RT D'Amico Risk Group				–	–	–
Low risk	Ref	–	–			
Favorable Intermediate	0.67	0.38–1.19	0.17			
Unfavorable intermediate	1.26	0.58–2.74	0.55			
High risk	1.19	0.65–2.18	0.56			
Post – RT PSA nadir	1.17	0.85–1.59	0.33	–	–	–
ADT prior to S–HIFU						
None	Ref	–	–	–	–	–
short (<6 month)	0.99	0.56–1.76	0.99			
Long (≥6 months)	1.35	0.78–2.31	0.28			
Time between RT and S–HIFU	0.93	0.86–1.01	0.08	0.92	0.84–0.99	**0.04**
Pre–S–HIFU PSA	1.07	1.02–1.13	**0.02**	–	–	–
%Positive cores before S–HIFU	1.59	0.67–3.78	0.29	–	–	–
ISUP grade before S–HIFU						
1	Ref	–	–	Ref		
2	1.56	0.79–3.09	0.20	2.18	1.04–4.54	0.04
3	1.26	0.59–2.68	0.55	0.99	0.43–2.33	0.99
4	1.42	0.66–3.08	0.37	1.37		0.47
5	2.46	1.06–5.71	**0.03**	3.32	0.58–3.27 1.31–8.38	**0.01**
Age at S–HIFU	1.01	0.97–1.04	0.94	–	–	–
Prostate volume	1.01	0.99–1.03	0.36	–	–	–
Treatment completeness						
Complete	Ref	–	–	Ref	1.99–7.47	**<0.001**
Incomplete	2.59	1.42–4.73	**<0.01**	3.86		
PSA nadir post– S–HIFU	1.32	1.25–1.41	**<0.001**	1.38	1.27–1.49	**<0.001**

[11–13] — substantially lower than those reported for SRP [3].

In this context, less invasive local salvage strategies such as S-HIFU have been developed to maintain oncological efficacy while reducing treatment-related morbidity and may represent a complementary option for patients not eligible for or declining re-irradiation or surgery.

In our cohort, the 5-year PFS was 43.6%, with a median PFS of 41 months, comparable to previously reported outcomes ranging from 31% to 54% [14–21]. The 5-year metastasis-free survival (MFS) reached 85%, with a median MFS of 13.3 years, remaining within ranges described in prior studies (60–81%) [17, 22, 23]. Cancer-specific survival at 5 years was 95%, consistent with published series reporting rates between 81% and 100% [17, 21–24].

Several prognostic factors identified in our multivariable analysis align with previously reported data. High-grade disease, particularly ISUP grade group 5 tumors, has consistently been associated with poorer oncological outcomes. Baco et al. [25] reported significantly improved PFS in patients with Gleason score ≤ 7 compared with ≥ 8 disease. Similarly, a longer interval between radiotherapy and S-HIFU independently predicted improved PFS in our cohort, corroborating findings from Depaquit et al. [21]. Post-HIFU PSA nadir also emerged as a strong predictor of both PFS and MFS, further confirming its established prognostic value [15, 24].

Rectourethral fistula and pubic osteitis rates remained consistent with previously reported series [15, 17, 26]. Overall, major surgical intervention was required in 5.1% of cases, highlighting the non-negligible morbidity associated with salvage interventions in previously irradiated tissues.

Limitations

The selection criteria for whole-gland versus partial-gland S-HIFU — based on disease laterality and MRI-biopsy concordance — likely introduced a selection bias, as patients undergoing partial-gland treatment had inherently more localised disease. Notably, patients in the partial-gland group were older, had larger prostates, and had a longer interval from radiotherapy, which may have independently influenced both oncological and functional outcomes. This may partly explain the comparable oncological outcomes despite less extensive ablation, and should be considered when interpreting the results. In the absence of a randomised design, the comparison between whole-gland and partial-gland S-HIFU should therefore be considered hypothesis-generating as previously reported [22, 25, 27].

Our study benefits from a large cohort and long-term follow-up from a high-volume center; however, several limitations inherent to its retrospective design must be acknowledged : The retrospective nature of this study did not allow systematic collection of detailed baseline tumour characteristics at the time of S-HIFU, including MRI lesion size, number and location of positive biopsy cores, multifocality, and formal MRI-biopsy concordance assessment — particularly in the earlier part of the cohort when multiparametric MRI was not yet routinely performed. While key prognostic variables such as pre-treatment PSA and ISUP grade group were systematically available and incorporated into multivariable analyses, the absence of granular tumour mapping data limits the precision of the comparison between whole-gland and partial-gland approaches and should be considered when interpreting the selection criteria and their impact on outcomes. Occult or newly developed lesions outside the treated zone cannot be excluded in patients who underwent hemi-gland or focal ablation without systematic confirmatory targeted biopsies prior to treatment.

The 17-year study period encompasses significant changes in several domains that may have influenced both oncological and functional outcomes: imaging modalities evolved from conventional bone scintigraphy and CT to choline-PET and more recently PSMA-PET, improving the detection of metastatic disease and influencing the timing of ADT initiation; biopsy techniques evolved from transrectal to transperineal approaches with increasing use of MRI-targeted fusion biopsies, which may have influenced staging accuracy [28, 29]. HIFU platforms changed from the Ablatherm® system (used until 2015) to the Focal One® platform (used thereafter), with differences in treatment planning; and systemic therapy options expanded substantially, with the emergence of next-generation androgen receptor inhibitors. Furthermore, the composite definition of disease progression — combining PSA > nadir + 2 ng/mL, ADT initiation, and positive control biopsies — carries inherent limitations. ADT initiation was a clinician-driven decision influenced by multiple factors including age, comorbidities, patient preference, PSA kinetics, and imaging findings, and was not systematically triggered by a predefined threshold, introducing heterogeneity in the timing of progression classification across the cohort. Control biopsies were not performed systematically, which may have led to under-detection of local persistence or recurrence, particularly in patients treated with partial-gland approaches where residual untreated tissue remained. Metastasis-directed therapies were not systematically offered, particularly in the earlier part of the cohort, as oligometastatic disease management evolved considerably over time. These temporal confounders limit the homogeneity of the cohort and should be considered when interpreting the results.

Of note, incomplete treatment — defined as failure to deliver the full planned ultrasound treatment programme — occurred in 14 patients (10.1%) of our cohort, reflecting the inherent variability of real-world clinical practice. Importantly, incomplete treatment was independently associated with a significantly higher risk of both disease progression and metastatic progression on multivariable analysis. These finding highlights that a non-negligible proportion of S-HIFU procedures cannot be completed as planned and should be factored into patient counselling and pre-procedural planning.

In patients with ISUP grade group 5 disease at salvage biopsy, S-HIFU may offer limited oncological control, as reflected by the significantly increased risk of both disease progression and metastatic spread observed in our multivariable analyses. In such cases, robotic-assisted salvage radical prostatectomy warrants consideration, as it provides the additional benefit of accurate pathological staging — including assessment of lymph node involvement — which may directly inform the decision between early and deferred androgen deprivation therapy. Multidisciplinary discussion is therefore essential in this high-risk subgroup, and S-HIFU should be reserved for patients in whom surgery is not feasible or declined.

The complication profile observed in our cohort warrants careful discussion. Severe complications (Clavien-Dindo grade ≥ 3) occurred in 48.3% of whole-gland and 29.8% of partial-gland S-HIFU patients, which compares unfavourably with re-irradiation series reporting severe genitourinary toxicity below 8% for both salvage brachytherapy and SBRT [3, 11–13]. While prior studies reported that severe genitourinary toxicity exceeds 21% for whole-gland S-HIFU [3], our rates appear higher — which may be explained by several factors. First, our series reflects real-world practice over 17 years with a long median follow-up exceeding five years, capturing late complications that

PFS

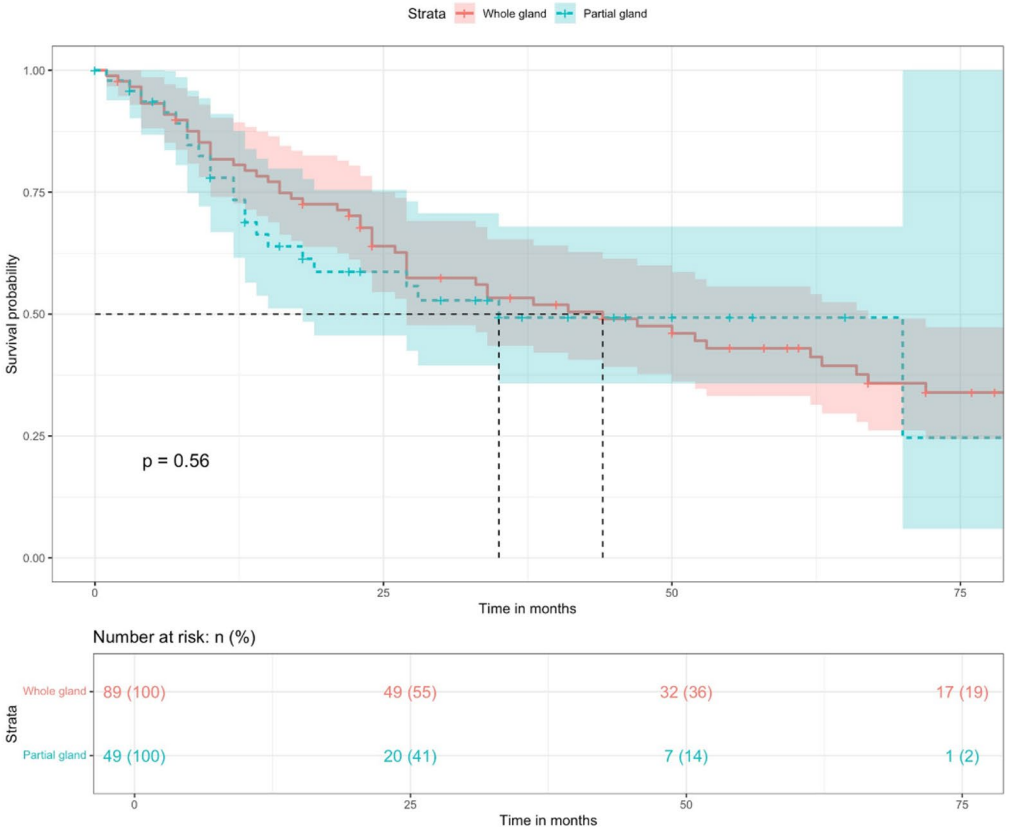
Strata Whole gland Partial gland
Survival probability
1.00
0.75
0.50
0.25
0.00
p = 0.56
0
25
50
75
Time in months
Number at risk: n (%)
Strata
Whole gland 89 (100) 49 (55) 32 (36) 17 (19)
Partial gland 49 (100) 20 (41) 7 (14) 1 (2)
0
25
50
75
Time in months

MFS

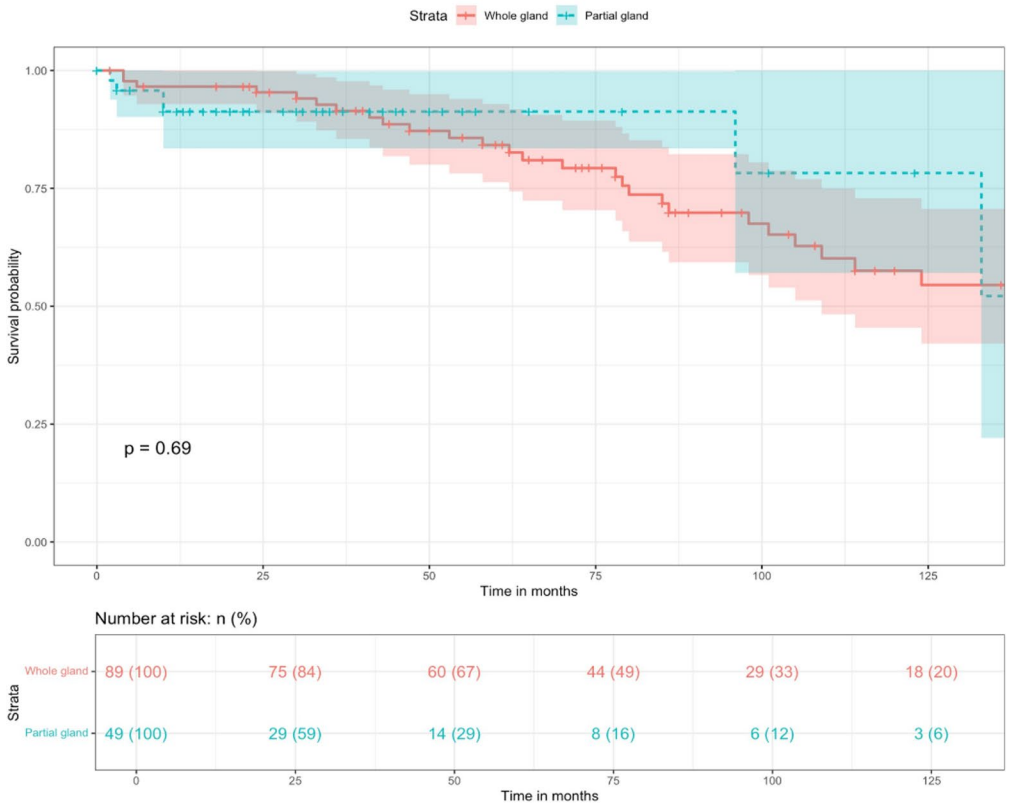
Strata Whole gland Partial gland
Survival probability
1.00
0.75
0.50
0.25
0.00
p = 0.69
0
25
50
75
100
125
Time in months
Number at risk: n (%)
Strata
Whole gland 89 (100) 75 (84) 60 (67) 44 (49) 29 (33) 18 (20)
Partial gland 49 (100) 29 (59) 14 (29) 8 (16) 6 (12) 3 (6)
0
25
50
75
100
125
Time in months

Fig. 3 Comparison between whole gland and partial gland S-HIFU for PFS **A** and MFS **B**

shorter in follow-up series may not have reported. Second, a significant proportion of procedures were performed in the early experience of S-HIFU at our institution, before optimization of treatment protocols. Third, patients undergoing re-irradiation or S-HIFU in other series may be more carefully selected based on preserved urinary function and favourable IPSS scores, whereas our cohort included patients with potentially compromised baseline urinary function following prior high-dose pelvic irradiation. Baseline IPSS scores were not systematically collected in our retrospective cohort and other functional outcomes were collected without validated PROMs precluding formal assessment of pre-existing radiation-induced lower urinary tract dysfunction and its potential contribution to postoperative urinary retention. Fourth, published re-irradiation series are generally smaller and shorter in follow-up, and the EAU guidelines themselves acknowledge that toxicity may be under-reported in these studies [2]. Finally, the significant reduction in severe complications observed with partial-gland S-HIFU in our series reinforces the importance of treatment de-escalation in appropriately selected patients and suggests that morbidity may be substantially reduced with contemporary techniques and refined patient selection.

Erectile function could not be systematically assessed due to heterogeneous documentation; this represents a limitation, as partial-gland approaches may offer better preservation of sexual function compared to whole-gland ablation [16, 30].

Although ADT remains frequently used in this setting, local salvage therapy should be considered whenever feasible to prevent locoregional progression and metastatic dissemination [31–33]. Integration of S-HIFU within multimodal strategies including next-generation androgen receptor inhibitors warrants prospective evaluation [34, 35].

A proposed clinical selection algorithm for S-HIFU candidate selection is illustrated in Supplementary Fig. 2.

Prospective comparative studies are warranted to further define the optimal integration of partial salvage approaches within contemporary multimodal management strategies for radiorecurrent prostate cancer.

Conclusion

According to the EAU guidelines, S-HIFU carries only a weak recommendation for radiorecurrent prostate cancer, reserved for highly selected patients, in contrast to SRP, brachytherapy, and SBRT which carry strong recommendations. This should be considered when interpreting our results, particularly considering the significant morbidity observed with whole-gland S-HIFU. Nevertheless, in patients for whom re-irradiation and surgery are not feasible or declined, and when appropriate selection criteria are met, our findings suggest that partial-gland S-HIFU may represent a valuable option — reducing the risk of severe complications without apparent compromise of oncological outcomes compared to whole-gland S-HIFU.

Supplementary Information The online version contains supplementary material available at https://doi.org/10.1007/s00345-026-06831-1.

Author contributions F.B., G.P., and T.H. contributed to the conception of the study. C.M. and G.P. were responsible for data acquisition. S.M., C.M., and F.B. performed the analysis and interpretation of data. C.M., S.M., and F.B. drafted the manuscript. F.B., G.R., T.H., and G.P. provided critical revision for important intellectual content. S.M. performed the statistical analysis. T.H. provided administrative support.

Funding This research did not receive any specific grant from funding agencies in the public, commercial, or not-for-profit sectors.

Data availability Data Sharing statement: The datasets generated and analyzed during the current study, as well as the statistical analysis code written in R, are available from the corresponding author upon reasonable request.

Declarations

Conflict of interest The authors declare no conflicts of interest.

Ethical approval This retrospective study was approved by the local institutional ethics committee. Patients were informed and included under a non-opposition procedure in accordance with national data protection regulations.

References

1. Beckendorf V, Guerif S, Le Prisé E, Cosset JM, Bougnoux A, Chauvet B et al (2011) 70 Gy versus 80 Gy in localized prostate cancer: 5-year results of GETUG 06 randomized trial. Int J Radiat Oncol Biol Phys 15 juill 80(4):1056–1063 .049 PubMed PMID: 21147514
2. EAU Guidelines on Prostate Cancer - Uroweb [Internet]. [cité 19 juin 2026]. Disponible sur: https://uroweb.org/guidelines/prostate-cancer
3. Valle LF, Lehrer EJ, Markovic D, Elashoff D, Levin-Epstein R, Karnes RJ et al (2021) A Systematic Review and Meta-analysis of Local Salvage Therapies After Radiotherapy for Prostate Cancer (MASTER). Eur Urol sept 80(3):280–292 PubMed PMID: 33309278; PubMed Central PMCID: PMC10262981
4. Sanderson KM, Penson DF, Cai J, Groshen S, Stein JP, Lieskovsky G et al (2006) Salvage Radical Prostatectomy: Quality of Life Outcomes and Long-Term Oncological Control of Radiorecurrent Prostate Cancer. J Urol nov 176(5):2025–2032. https://doi.org/10.1016/j.juro.2006.07.075
5. Tran H, Kwok J, Pickles T, Tyldesley S, Black PC (2014) Underutilization of local salvage therapy after radiation therapy for prostate cancer11Funding: UBC Summer Student Research Program.

Urologic Oncology: Seminars Original Investigations juill 32(5):701–706. https://doi.org/10.1016/j.urolonc.2013.12.014
6. Agarwal PK, Sadetsky N, Konety BR, Resnick MI, Carroll PR, Cancer of the Prostate Strategic Urological Research Endeavor (CaPSURE) (2008) Treatment failure after primary and salvage therapy for prostate cancer: likelihood, patterns of care, and outcomes. Cancer 15 janv 112(2):307–314. https://doi.org/10.1002/cncr.23161 PubMed PMID: 18050294
7. Henderson RH, Bryant C, Nichols RC, Mendenhall WM, Mendenhall NP (2023) Local salvage of radiorecurrent prostate cancer. Prostate 1 août 83(11):1001–1010. https://doi.org/10.1002/pros.24551
8. Roach M, Hanks G, Thames H, Schellhammer P, Shipley WU, Sokol GH et al (2006) Defining biochemical failure following radiotherapy with or without hormonal therapy in men with clinically localized prostate cancer: Recommendations of the RTOG-ASTRO Phoenix Consensus Conference. International Journal of Radiation Oncology Biology Physics. juill. ;65(4):965–74. https://doi.org/10.1016/j.ijrobp.2006.04.029
9. Dindo D, Demartines N, Clavien PA (2004) Classification of Surgical Complications: A New Proposal With Evaluation in a Cohort of 6336 Patients and Results of a Survey. Annals Surg août 240(2):205–213. https://doi.org/10.1097/01.sla.0000133083.54934.ae
10. Chade DC, Eastham J, Graefen M, Hu JC, Karnes RJ, Klotz L et al (2012) Cancer control and functional outcomes of salvage radical prostatectomy for radiation-recurrent prostate cancer: a systematic review of the literature. Eur Urol mai 61(5):961–971. https://doi.org/10.1016/j.eururo.2012.01.022 PubMed PMID: 22280856
11. Cuccia F, Mazzola R, Nicosia L, Giaj-Levra N, Figlia V, Ricchetti F et al (2020) Prostate re-irradiation: current concerns and future perspectives. Expert Rev Anticancer Therapy 1 nov 20(11):947–956. https://doi.org/10.1080/14737140.2020.1822742
12. Pasquier D, Lacornerie T, Supiot S, Pommier P, Quivrin M, Simon JM et al (2023) The Safety and Efficacy of Salvage Stereotactic Radiation Therapy in Patients with Intraprostatic Tumor Recurrence After Previous External Radiation Therapy: Phase 1 Results from the GETUG-AFU 31 Study. Eur Urol Oncol 1 août 6(4):399–405. https://doi.org/10.1016/j.euo.2023.01.009 PubMed PMID: 36754722
13. Cuccia F, Nicosia L, Mazzola R, Figlia V, Giaj-Levra N, Ricchetti F et al (2020) Linac-based SBRT as a feasible salvage option for local recurrences in previously irradiated prostate cancer. Strahlenther Onkol juill 196(7):628–636. https://doi.org/10.1007/s00066-020-01628-6
14. Sobhani S, Dadabhoy A, Ghoreifi A, Lebastchi AH (2024) Salvage High-Intensity Focused Ultrasound for Prostate Cancer after Radiation Failure: A Narrative Review. Curr Oncol 26 juin 31(7):3669–3681. https://doi.org/10.3390/curroncol31070270 PubMed PMID: 39057142; PubMed Central PMCID: PMC11276396
15. Shah TT, Peters M, Kanthabalan A, McCartan N, Fatola Y, van der Voort J et al (2016) PSA nadir as a predictive factor for biochemical disease-free survival and overall survival following whole-gland salvage HIFU following radiotherapy failure. Prostate Cancer Prostatic Dis sept 19(3):311–316. https://doi.org/10.1038/pcan.2016.23 PubMed PMID: 27431499; PubMed Central PMCID: PMC4983180
16. Kanthabalan A, Peters M, Van Vulpen M, McCartan N, Hindley RG, Emara A et al (2017) Focal salvage high-intensity focused ultrasound in radiorecurrent prostate cancer. BJU Int août 120(2):246–256. https://doi.org/10.1111/bju.13831 PubMed PMID: 28258616
17. Crouzet S, Blana A, Murat FJ, Pasticier G, Brown SCW, Conti GN et al (2017) Salvage high-intensity focused ultrasound (HIFU) for locally recurrent prostate cancer after failed radiation therapy: Multi-institutional analysis of 418 patients. BJU Int juin 119(6):896–904. https://doi.org/10.1111/bju.13766
18. Rouvière O, Sbihi L, Gelet A, Chapelon JY (2013) Salvage high-intensity focused ultrasound ablation for prostate cancer local recurrence after external-beam radiation therapy: Prognostic value of prostate MRI. Clin Radiol juill 68(7):661–667. https://doi.org/10.1016/j.crad.2012.12.010
19. Dason S, Wong NC, Allard CB, Hoogenes J, Orovan W, Shayegan B (2018) High-Intensity Focused Ultrasound (HIFU) as salvage therapy for radio-recurrent prostate cancer: predictors of disease response. Int Braz J Urol 44(2):248–257 2017.0025 PubMed PMID: 29211405; PubMed Central PMCID: PMC6050568
20. Song W, Jung US, Suh YS, Jang HJ, Sung HH, Jeon HG et al (2014) High-Intensity Focused Ultrasound as Salvage Therapy for Patients With Recurrent Prostate Cancer After Radiotherapy. Korean J Urol févr 55(2):91–96 .91 PubMed PMID: 24578803; PubMed Central PMCID: PMC3935076
21. Depaquit TL, Campagna J, Bastide C, Baboudjian M, Corral R, Uleri A et al (2024) Salvage High-intensity Focused Ultrasound (S-HIFU) for Recurrence after Primary Radiotherapy of Prostate Cancer. Fr J Urol 26 mars 102633. https://doi.org/10.1016/j.fjurol.2024.102633 PubMed PMID: 38547931
22. Hostiou T, Gelet A, Chapelon JY, Rouvière O, Mège-Lechevalier F, Lafon C et al (2019) Salvage high-intensity focused ultrasound for locally recurrent prostate cancer after low-dose-rate brachytherapy: oncological and functional outcomes. BJU Int 124(5):746–757. https://doi.org/10.1111/bju.14838
23. Devos B, Al Hajj Obeid W, Andrianne C, Diamand R, Peltier A, Everaerts W et al (2019) Salvage high-intensity focused ultrasound versus salvage radical prostatectomy for radiation-recurrent prostate cancer: a comparative study of oncological, functional, and toxicity outcomes. World J Urol août 37(8):1507–1515. https://doi.org/10.1007/s00345-019-02640-x
24. Siddiqui KM, Billia M, Arifin A, Li F, Violette P, Chin JL (2017) Pathological, Oncologic and Functional Outcomes of a Prospective Registry of Salvage High Intensity Focused Ultrasound Ablation for Radiorecurrent Prostate Cancer. J Urol janv 197(1):97–102. https://doi.org/10.1016/j.juro.2016.06.092
25. Baco E, Gelet A, Crouzet S, Rud E, Rouvière O, Tonoli-Catez H et al (2014) Hemi salvage high-intensity focused ultrasound (HIFU) in unilateral radiorecurrent prostate cancer: a prospective two-centre study. BJU Int oct 114(4):532–540. https://doi.org/10.1111/bju.12545
26. Zacharakis E, Ahmed HU, Ishaq A, Scott R, Illing R, Freeman A et al (2008) The feasibility and safety of high-intensity focused ultrasound as salvage therapy for recurrent prostate cancer following external beam radiotherapy. BJU Int oct 102(7):786–792. https://doi.org/10.1111/j.1464-410X.2008.07775.x
27. Ahmed HU, Cathcart P, McCartan N, Kirkham A, Allen C, Freeman A et al (2012) Focal salvage therapy for localized prostate cancer recurrence after external beam radiotherapy: A pilot study. Cancer sept 118(17):4148–4155. https://doi.org/10.1002/cncr.27394
28. Marenco Jimenez JL, Claps F, Ramón-Borja JC, Mascarós Martinez JM, Gutierrez AW, Lozano ÁGF et al (2021) Rebiopsy rate after transperineal or transrectal prostate biopsy. Prostate Int juin 9(2):78–81. https://doi.org/10.1016/j.prnil.2020.10.001 PubMed PMID: 34386449; PubMed Central PMCID: PMC8322821
29. Hu JC, Assel M, Allaf ME, Vickers AJ, Ehdaie B, Cohen AJ et al (2024) Transperineal vs Transrectal Prostate Biopsy—The PREVENT Randomized Clinical Trial. JAMA Oncol 1 nov 10(11):1590–1593. https://doi.org/10.1001/jamaoncol.2024.4000
30. Jones TA, Chin J, Mcleod D, Barkin J, Pantuck A, Marks LS (2018) High Intensity Focused Ultrasound for Radiorecurrent

Prostate Cancer: A North American Clinical Trial. J Urol janv 199(1):133–139. https://doi.org/10.1016/j.juro.2017.06.078
31. Zumsteg ZS, Spratt DE, Romesser PB, Pei X, Zhang Z, Polkinghorn W et al (2015) The natural history and predictors of outcome following biochemical relapse in the dose escalation era for prostate cancer patients undergoing definitive external beam radiotherapy. Eur Urol juin 67(6):1009–1016 .028 PubMed PMID: 25308970; PubMed Central PMCID: PMC5002994
32. Yokomizo A, Wakabayashi M, Satoh T, Hashine K, Inoue T, Fujimoto K et al (2020) Salvage Radiotherapy Versus Hormone Therapy for Prostate-specific Antigen Failure After Radical Prostatectomy: A Randomised, Multicentre, Open-label, Phase 3 Trial (JCOG0401)†. Eur Urol juin 77(6):689–698. https://doi.org/10.1016/j.eururo.2019.11.023
33. Siddiqui SA, Boorjian SA, Inman B, Bagniewski S, Bergstralh EJ, Blute ML (2008) Timing of androgen deprivation therapy and its impact on survival after radical prostatectomy: a matched cohort study. J Urol mai 179(5):1830–1837 discussion 1837. https://doi.org/10.1016/j.juro.2008.01.022
34. Shore ND, de Almeida Luz M, De Giorgi U, Gleave M, Gotto GT, Haas GP, LBA02-09 Embark: a phase 3 randomized study of enzalutamide or placebo plus leuprolide acetate and enzalutamide monotherapy in high-risk biochemically recurrent prostate cancer [Internet]. [cité 20 juin 2026]. https://www.auajournals.org/doi/epdf/ https://doi.org/10.1097/JU.0000000000003361.09 doi:10.1097/JU.0000000000003361.09
35. Sciarra A, Santarelli V, Salciccia S, Moriconi M, Basile G, Santodirocco L et al (2024) How the Management of Biochemical Recurrence in Prostate Cancer Will Be Modified by the Concept of Anticipation and Incrementation of Therapy. Cancers (Basel) 13 févr 16(4):764. https://doi.org/10.3390/cancers16040764 PubMed PMID: 38398155; PubMed Central PMCID: PMC10886975

Publisher's note Springer Nature remains neutral with regard to jurisdictional claims in published maps and institutional affiliations.

Springer Nature or its licensor (e.g. a society or other partner) holds exclusive rights to this article under a publishing agreement with the author(s) or other rightsholder(s); author self-archiving of the accepted manuscript version of this article is solely governed by the terms of such publishing agreement and applicable law.